

Is The Late Mandibular Fracture From Third Molar Extraction a Risk Towards Malpractice? Case Report with the Analysis of Ethical and Legal Aspects

Weuler dos Santos Silva¹, Rubens Jorge Silveira², Michelle Gouveia Benicio de Araujo Andrade³, Ademir Franco⁴, Rhonan Ferreira Silva⁵

¹Department of Maxillofacial Surgery, Public Hospital of Urgency, Anapolis, Brazil.

²Department of Maxillofacial Surgery, Paulista University, Goiania, Brazil.

³Department of Maxillofacial Surgery, Hospital Cidade Jardim, Goiania, Brazil.

⁴Department of Stomatology, Federal University of Parana, Parana, Brazil.

⁵Legal Odontology, Federal University of Goias, Goiania, Brazil.

Corresponding Author:

Rhonan Ferreira Silva

Legal Odontology, Universidade Federal de Goias

Av. Universitaria, Esquina com 1^a Avenida s/n, Setor Universitario

74605-220, Goiania, Goias

Brazil

Phone: 00 55 62 3209 6051

E-mail: rhonansilva@gmail.com

ABSTRACT

Objectives: The present study reports a case of late mandibular fracture due to third molar extraction and highlights the inherent clinical, ethical and legal aspects related to this surgical complication.

Material and Methods: A female patient underwent surgical procedure for the extraction of the mandibular right third molar. Two days after the surgery the patient reported pain and altered occlusion in the right side of the mandible. After clinical and radiographic re-examination, the diagnosis of late mandibular fracture was established. A second surgery, under general anaesthesia, was performed for the fixation of the mandibular bone.

Results: The fractured parts were reduced and fixed with locking plate systems and 2 mm screws following load-sharing principles. The masticatory function showed optimal performance within 7 and 21 days after the surgery. Complete bone healing was observed within 1 year of follow-up.

Conclusions: For satisfactory surgical outcomes, adequate surgical planning and techniques must be performed. Signed informed consents explaining the risks and benefits of the treatment must be used to avoid ethical and legal disputes in dentistry.

Keywords: malpractice; mandibular fracture; oral surgery; third molar; tooth extraction.

Accepted for publication: 29 June 2017

To cite this article:

dos Santos Silva W, Silveira RJ, de Araujo Andrade MGB, Franco A, Silva RF.

Is The Late Mandibular Fracture From Third Molar Extraction a Risk Towards Malpractice? Case Report with the Analysis of Ethical and Legal Aspects

J Oral Maxillofac Res 2017;8(2):e5

URL: <http://www.ejomr.org/JOMR/archives/2017/2/e5/v8n2e5.pdf>

doi: [10.5037/jomr.2017.8205](https://doi.org/10.5037/jomr.2017.8205)

INTRODUCTION

Third molar extraction figures amongst the most common procedures in oral surgery [1]. This procedure is performed both by maxillofacial surgeons and general clinicians in the routine of dental services [1]. As any other surgical procedure, third molar extraction may lead to accidents and complications [2], such as haemorrhage [3], emphysema [4], displacement to orofacial spaces [5], infections [6], bone fractures [6] and nerve injuries [7].

Specifically in relation to bone fractures, the extraction of mandibular third molars play a major part compared to first and second molars and impacted canines [6]. These fractures may occur in the trans- and postoperative periods [8]; may involve young and adult patients [9,10]; may be associated with impacted or erupted third molars [9,10]; and may be caused due to the position of the tooth in the mandible (increasing the fragility in the region of mandibular angle) or due to improper surgical performance [11]. Once diagnosed with mandibular fracture, the patient must be informed and referred to services specialized in maxillofacial surgery for managing the condition and avoid further clinical, ethical and legal complications [12]. Knowing the risks, as well the clinical, ethical and legal complications from third molar extractions may support the dentists in the daily practice.

Based on the exposed, the present study aims to report a case of late mandibular fracture due to third molar extraction and highlights the clinical, ethical and legal aspects related to this surgical complication.

CASE DESCRIPTION AND RESULTS

A 33-year-old Caucasian female patient was referred to

a private dental clinic in the city of Anapolis, State of Goias, Brazil, complaining of swelling and inflammation of the mandibular right third molar (tooth number 48).

After the anamnesis, no systemic alterations that could interfere with the surgical procedure were detected. Panoramic and periapical radiographs were requested and revealed that tooth #48 was partially erupted and tilted distally (Pell and Gregory's classification: IIB [13]) (Figure 1). Clinically, pericoronitis was observed involving tooth #48. Anti-inflammatory (Ibuprofen 600 mg) on every 12 hours, and Antibiotic (Amoxicillin 500 mg) on every 8 hours, were prescribed covering a period of 3 and 7 days, respectively.

After the preoperative treatment, the surgery was performed extracting firstly the maxillary right and left third molars with local anaesthesia using Lidocaine 2% with adrenaline 1:100.000 (Nova DFL[®], Rio de Janeiro, Brazil). Next, tooth #48 was assessed blocking the mandibular nerve with the same anaesthetic drug and performing an envelope incision, with a mucoperiosteal flap detachment from the retromolar trigone to the medial surface of the mandibular left first molar. Difficulty was found in this procedure, making necessary the use of high-speed drills for transversal odontotomy. The tooth was extracted in the same day.

Two days after the surgery the patient contacted the dentist complaining of pain and altered occlusion. The patient was re-examined and the diagnosis of late mandibular fracture was considered. In the 10th day after surgery the patient was referred to a maxillofacial surgeon with altered occlusion and mobility in the right side of the mandible. Radiographically, the mandibular fracture was confirmed. The right mandibular angle was involved and the fractured parts were displaced (Figure 2).

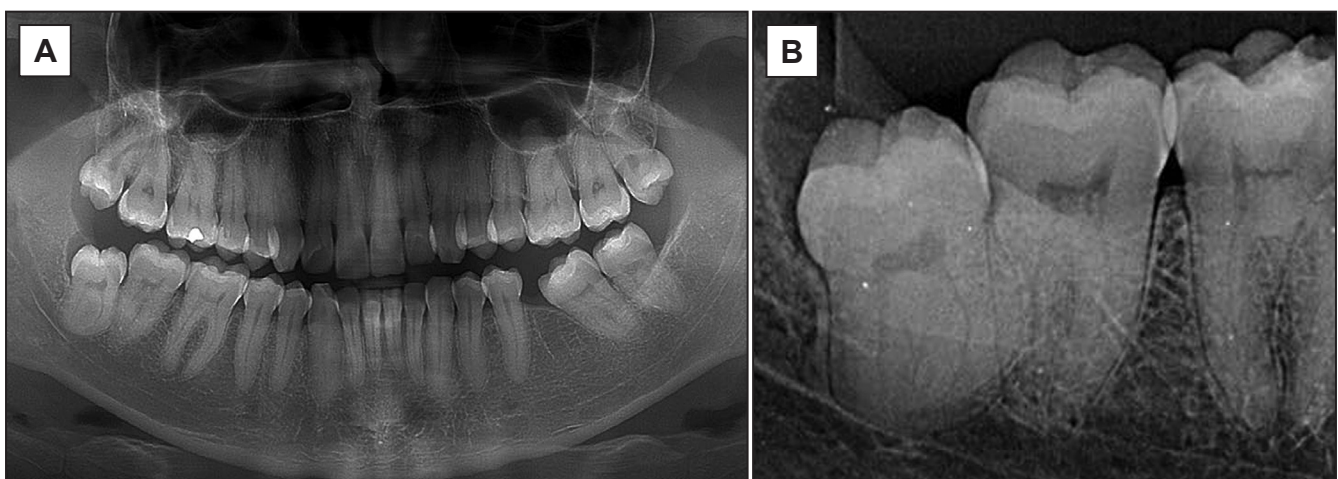


Figure 1. Radiographs requested for third molar extraction: A = preoperative panoramic; B = periapical.

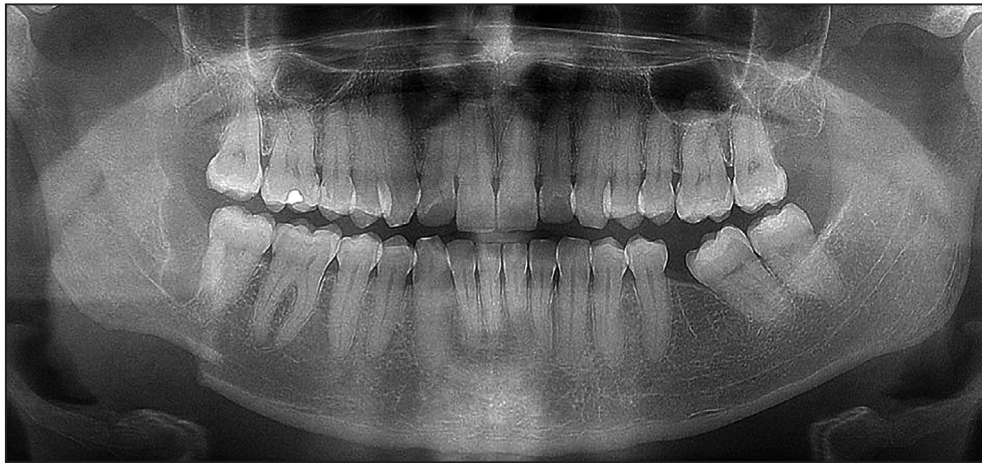


Figure 2. Postoperative panoramic radiograph revealing the late mandibular fracture on the right side.

The patient underwent preoperative planning with an orthodontist (for the placement of brackets) and with a maxillofacial surgeon (for maxillomandibular fixation with steel wires n.1). Surgical reassessment was performed in a public hospital in the same city, under general anaesthesia, and nasotracheal intubation. Extraoral access was performed in the submandibular region using Risdon's technique to expose the fracture. The fractured parts were reduced and fixed with locking plate systems and 2 mm screws according to Champy's technique following load-sharing principles.

The patient remained in the hospital for a day progressing without additional complications. In the following days, Class III elastics were used to guide the occlusion. The patient was advised for non-solid foods in the early postoperative days. The masticatory function was assessed within 7 and 21 days after the surgery showing optimal performance. Physiotherapy with low-level laser therapy was prescribed to stimulate the inferior alveolar nerve because the patient reported diminished sensitivity.

Within one year, the patient re-established

the masticatory function and occlusion and presented complete bone healing (Figure 3). However, reports on the reduced sensitivity of the lower lip persisted.

DISCUSSION

Third molar extraction consists of a surgical procedure with high prevalence in the daily practice of general clinicians and maxillofacial surgeons. In most of the cases, this procedure is performed without trans- and postoperative complications. On the other hand, the unsuccessful procedures may be justified by the lack of adequate preoperative surgical planning and transoperative surgical performance [14]. Yet these procedures contribute to the increasing medical litigation [15].

The field of oral and maxillofacial surgery has an especial condition in the spotlight of justice due to the important risks involved within each procedure. Despite the differences in legal proceedings and ethical guidelines inherent to country-specific laws and professional regulatory bodies,

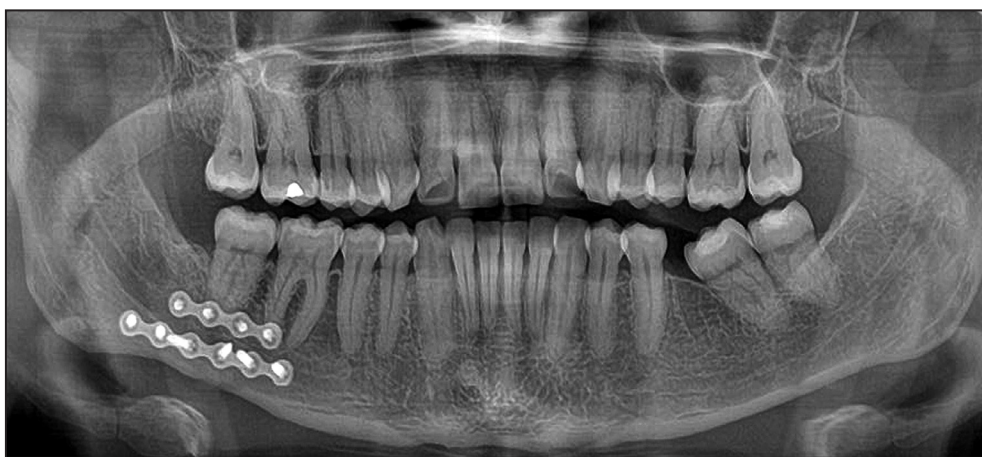

Figure 3. Postoperative panoramic radiograph after the fixation of the mandibular fracture registered within 1-year follow-up.

claims on supposed malpractice involving dentists enlarged worldwide. In Brazil, oral and maxillofacial surgery was pointed as the second most suited ($n = 97$) specialty of dentistry between 2013 and 2014 concerning civil litigations in the Court of São Paulo ($n = 23$ cases, 23.71%) [16]. Indemnifications reached nearly 21 thousand dollars for the reparation of non-material damages [16]. In Spain, oral and maxillofacial surgery figured in the third position among the most suited dental specialties between 2000 and 2010 ($n = 84$ cases, 20.24%) [17]. In a larger scenario (from 1995 to 2010), United Kingdom claims on oral and maxillofacial surgery ($n = 318$) registered 28 cases in which bone injury or fracture was reported after a surgical intervention [15]. Further on, a recent study performed within the Finnish jurisprudence approached more specifically the surgical complications from tooth extraction [18]. In this study, a total of 852 malpractice claims were detected and analysed between 1997 and 2010, from which third molars emerged as the tooth most involved (66%) [18]. However, most of the injuries from third molar extractions affected the inferior alveolar nerve and not the mandible bone.

These studies reveal that legal claims founded on late mandibular fractures from third molar extractions are hardly found in the literature, becoming an uncommon (but important) condition [19,20] - with estimated prevalence rates as low as 0.0049% (37 out of 750 thousand extractions) [10]. These fractures may occur due the dissemination of pathological lesions such as tumours, and modalities of trauma, such as by firearm injuries, aggression, traffic accidents, contact sports, occupational accidents [21] and malpractice during surgeries [20]. The late mandibular fracture diagnosed in the present case was justified on the altered occlusion and pain claimed by the patient especially in the second day postoperative. Nearly 80% of the cases of mandibular fractures express alterations in occlusion [22]. Specifically in this case, the late mandibular fracture resulted possibly from the combination of forces from the masticatory muscles over the mandible that was already fragile after third molar extraction. It is important to note that the late mandibular fracture affected the posterior region of the mandible. Besides the fragile bone support that remained after the surgery, strong muscles attach in the posterior region of the mandible, namely the masseter and medial pterygoid [22]. Traction vectors promoted by these muscles together with the forces of other muscles involved in mandible movement (such as the digastrics) played an important part towards the fracture. In face of the potential risks of late mandibular fractures, patients must be informed

clearly on the chewing phenomenon and the muscle forces that may affect the fragile surgical site. Additional causes, other than masticatory forces may lead to late mandibular fractures, such as systemic disorders that include bone fragilization and local trauma with impact on the surgical site. These causes were excluded in the present case because they were not reported by the patient in the pre- (systemic disorders) and postoperative (local trauma) anamnesis. With 2 cases of mandibular fractures from third molar extractions detected out of 20, Marei [23], in 2013, focused in highlighting that most of the complications from oral surgery can be avoided with optimal preoperative planning and communication between professional and patient. More specifically, the lack of information provided to the patient may support strongly claims of malpractice. In this context, the informed consent arises as an essential tool to improve communication and defend the dentists against accusations and claims [24]. The informed consent is included among the risk management strategies to guide the best practices in dentistry [25]. Mandible fractures are considered rare complications in oral surgery [25]. The potential risks inherent to these complications are not often explained to the patient in the regular routine surgical services. Keeping the patients informed is an essential step towards an optimal professional relation in the routine of dentistry - especially when more complex dental extractions are expected, such as the ones involving unerupted third molars [25]. The informed consent plays a significant part in this scenario as a tool for clinical communication. More specifically, it gives to the patient the right to agree or not with the treatment proposed by the dentist [26]. Consequently, the informed consent may avoid legal and ethical disputes from surgical complications.

Above all the circumstances, the dentist involved with the mandibular fracture must provide any clinical and even financial support to the patient in order to contribute to a quicker healing process and minimize the potential sequels.

CONCLUSIONS

Mandibular fractures caused by dental extractions are uncommon and avoidable complications in the routine of dentistry. In order to reach satisfactory surgical outcomes, the dentists must perform adequate surgical planning and follow properly the techniques for dental extraction. Additionally, dentists must know the limits of their own skills before approaching challenging cases. On the other hand, even with

the optimal surgical approach, late mandibular fracture may occur because the healing process also depends on the patient's biological response. In these situations, the signed informed consent containing all the information on the risks of the dental extractions plays an essential part as a primary tool to protect the dentist against ethical and legal disputes.

ACKNOWLEDGEMENTS AND DISCLOSURE STATEMENTS

The authors report no conflicts of interest related to this study.

REFERENCES

1. Lee CT, Zhang S, Leung YY, Li SK, Tsang CC, Chu CH. Patients' satisfaction and prevalence of complications on surgical extraction of third molar. *Patient Prefer Adherence*. 2015 Feb 10;9:257-63. [Medline: [25709411](#)] [PMC free article: [4332291](#)] [doi: [10.2147/PPA.S76236](#)]
2. Sigron GR, Pourmand PP, Mache B, Stadlinger B, Locher MC. The most common complications after wisdom-tooth removal: part 1: a retrospective study of 1,199 cases in the mandible. *Swiss Dent J*. 2014;124(10):1042-6, 1052-6. English, German. [Medline: [25342545](#)]
3. Bianchi B, Varazzani A, Ferri A, Menozzi R, Sesenna E. Endovascular embolization for the management of inferior alveolar artery bleeding after a third molar extraction: A case report. *Quintessence Int*. 2016 Mar;47(3):227-31. [Medline: [26665260](#)] [doi: [10.3290/j.qi.a35261](#)]
4. Romeo U, Galanakis A, Lerario F, Daniele GM, Tenore G, Palaia G. Subcutaneous emphysema during third molar surgery: a case report. *Braz Dent J*. 2011;22(1):83-6. [Medline: [21519655](#)] [doi: [10.1590/S0103-64402011000100015](#)]
5. Silveira RJ, Garcia RR, Botelho TL, Franco A, Silva RF. Accidental displacement of third molar into the sublingual space: a case report. *J Oral Maxillofac Res*. 2014 Oct 1;5(3):e5. [Medline: [25386232](#)] [PMC free article: [4219864](#)] [doi: [10.5037/jomr.2014.5305](#)]
6. Bodner L, Brennan PA, McLeod NM. Characteristics of iatrogenic mandibular fractures associated with tooth removal: review and analysis of 189 cases. *Br J Oral Maxillofac Surg*. 2011 Oct;49(7):567-72. [Medline: [20947226](#)] [doi: [10.1016/j.bjoms.2010.09.007](#)]
7. Sarikov R, Juodzbalys G. Inferior alveolar nerve injury after mandibular third molar extraction: a literature review. *J Oral Maxillofac Res*. 2014 Dec 29;5(4):e1. [Medline: [25635208](#)] [PMC free article: [4306319](#)] [doi: [10.5037/jomr.2014.5401](#)]
8. Özçakir-Tomruk C, Arslan A. Mandibular angle fractures during third molar removal: a report of two cases. *Aust Dent J*. 2012 Jun;57(2):231-5. [Medline: [22624767](#)] [doi: [10.1111/j.1834-7819.2012.01674.x](#)]
9. Wagner KW, Schoen R, Wongchuensoontorn C, Schmelzeisen R. Complicated late mandibular fracture following third molar removal. *Quintessence Int*. 2007 Jan;38(1):63-5. [Medline: [17216910](#)]
10. Libersa P, Roze D, Cachart T, Libersa JC. Immediate and late mandibular fractures after third molar removal. *J Oral Maxillofac Surg*. 2002 Feb;60(2):163-5; discussion 165-6. [Medline: [11815913](#)] [doi: [10.1053/joms.2002.29811](#)]
11. Chrcanovic BR, Custódio AL. Considerations of mandibular angle fractures during and after surgery for removal of third molars: a review of the literature. *Oral Maxillofac Surg*. 2010 Jun;14(2):71-80. [Medline: [20091416](#)] [doi: [10.1007/s10006-009-0201-5](#)]
12. Hupp JR. Legal implications of third molar removal. *Oral Maxillofac Surg Clin North Am*. 2007 Feb;19(1):129-36, viii. [Medline: [18088871](#)] [doi: [10.1016/j.coms.2006.11.008](#)]
13. Pell GJ, Gregory BT. Impacted third molars classification and modified technique for removal. *Dent Digest*. 1933 Sep;39(9):330-8.
14. Bouloux GF, Steed MB, Perciaccante VJ. Complications of third molar surgery. *Oral Maxillofac Surg Clin North Am*. 2007 Feb;19(1):117-28, vii. [Medline: [18088870](#)] [doi: [10.1016/j.coms.2006.11.013](#)]
15. Gulati A, Herd MK, Nimako M, Anand R, Brennan PA. Litigation in National Health Service oral and maxillofacial surgery: review of the last 15 years. *Br J Oral Maxillofac Surg*. 2012 Jul;50(5):385-8. [Medline: [21788098](#)] [doi: [10.1016/j.bjoms.2011.06.003](#)]
16. Zanin AA, Herrera LM, Melani RF. Civil liability: characterization of the demand for lawsuits against dentists. *Braz Oral Res*. 2016 Aug 18;30(1). pii: S1806-83242016000100276. [Medline: [27556556](#)] [doi: [10.1590/1807-3107BOR-2016.vol30.0091](#)]
17. Perea-Pérez B, Labajo-González E, Santiago-Sáez A, Albarrán-Juan E, Villa-Vigil A. Analysis of 415 adverse events in dental practice in Spain from 2000 to 2010. *Med Oral Patol Oral Cir Bucal*. 2014 Sep 1;19(5):e500-5. [Medline: [24880444](#)] [PMC free article: [4192575](#)] [doi: [10.4317/medoral.19601](#)]
18. Koskela S, Suomalainen A, Apajalahti S, Ventä I. Malpractice claims related to tooth extractions. *Clin Oral Invest*. 2017 Mar;21(2):519-22. [Medline: [27511213](#)] [doi: [10.1007/s00784-016-1896-y](#)]
19. Custodio ALN, Menezes Junior DC, Cavalcanti FBN, Serpa MR, Cosso MG, Faria JMP. Considerations above the treatment of mandibular fracture after third molar removal. *Arq Bras Odontol*. 2007 Nov;3(2):106-13.

20. Marciani RD. Third molar removal: an overview of indications, imaging, evaluation, and assessment of risk. *Oral Maxillofac Surg Clin North Am.* 2007 Feb;19(1):1-13, v. [Medline: [18088860](#)] [doi: [10.1016/j.coms.2006.11.007](#)]
21. Silva RR, Rosa O, Taís FT, Marcos AF. Mandibular fracture cases in Pelotas, Rio Grande do Sul, Brazil. *RGO.* 2009 Jul-Sep;57(3):329-34.
22. Koshy JC, Feldman EM, Chike-Obi CJ, Bullocks JM. Pearls of mandibular trauma management. *Semin Plast Surg.* 2010 Nov;24(4):357-74. [Medline: [22550460](#)] [PMC free article: [3324216](#)] [doi: [10.1055/s-0030-1269765](#)]
23. Marei HF. Medical litigation in oral surgery practice: lessons learned from 20 lawsuits. *J Forensic Leg Med.* 2013 May;20(4):223-5. [Medline: [23622463](#)] [doi: [10.1016/j.jflm.2012.09.025](#)]
24. Curley AW. The law and dentoalveolar complications: trends and controversies. *Oral Maxillofac Surg Clin North Am.* 2011 Aug;23(3):475-84. [Medline: [21798444](#)] [doi: [10.1016/j.coms.2011.04.003](#)]
25. Henderson SJ. Risk management in clinical practice. Part 11. Oral surgery. *Br Dent J.* 2011 Jan 8;210(1):17-23. [Medline: [21217722](#)] [doi: [10.1038/sj.bdj.2010.1182](#)]
26. Badenoch-Jones EK, Lynham AJ, Loessner D. Consent for third molar tooth extractions in Australia and New Zealand: a review of current practice. *Aust Dent J.* 2016 Jun;61(2):203-7. [Medline: [26031850](#)] [doi: [10.1111/adj.12339](#)]

To cite this article:

dos Santos Silva W, Silveira RJ, de Araujo Andrade MGB, Franco A, Silva RF.

Is The Late Mandibular Fracture From Third Molar Extraction a Risk Towards Malpractice? Case Report with the Analysis of Ethical and Legal Aspects

J Oral Maxillofac Res 2017;8(2):e5

URL: <http://www.ejomr.org/JOMR/archives/2017/2/e5/v8n2e5.pdf>

doi: [10.5037/jomr.2017.8205](#)

Copyright © dos Santos Silva W, Silveira RJ, de Araujo Andrade MGB, Franco A, Silva RF. Published in the JOURNAL OF ORAL & MAXILLOFACIAL RESEARCH (<http://www.ejomr.org>), 30 June 2017.

This is an open-access article, first published in the JOURNAL OF ORAL & MAXILLOFACIAL RESEARCH, distributed under the terms of the [Creative Commons Attribution-Noncommercial-No Derivative Works 3.0 Unported License](#), which permits unrestricted non-commercial use, distribution, and reproduction in any medium, provided the original work and is properly cited. The copyright, license information and link to the original publication on (<http://www.ejomr.org>) must be included.