

Scalloped Implant-Abutment Connection Compared to Conventional Flat Implant-Abutment Connection: a Systematic Review and Meta-Analysis

Thomas Starch-Jensen¹, Ann-Eva Christensen², Henning Lorenzen¹

¹Department of Oral and Maxillofacial Surgery, Aalborg University Hospital, Aalborg, Denmark.

²Unit of Epidemiology and Biostatistics, Aalborg University Hospital, Aalborg, Denmark.

Corresponding Author:

Thomas Starch-Jensen

Department of Oral and Maxillofacial Surgery

Aalborg University Hospital

18-22 Hobrovej, DK-9000 Aalborg

Denmark

Phone: +45 97 66 27 98

Fax: +45 97 66 28 25

E-mail: thomas.jensen@rn.dk

ABSTRACT

Objectives: The objective was to test the hypothesis of no difference in implant treatment outcome after installation of implants with a scalloped implant-abutment connection compared to a flat implant-abutment connection.

Material and Methods: A MEDLINE (PubMed), Embase and Cochrane library search in combination with a hand-search of relevant journals was conducted. No language or year of publication restriction was applied.

Results: The search provided 298 titles. Three studies fulfilled the inclusion criteria. The included studies were characterized by low or moderate risk of bias. Survival of suprastructures has never been compared within the same study. High implant survival rate was reported in all the included studies. Significantly more peri-implant marginal bone loss, higher probing depth score, bleeding score and gingival score was observed around implants with a scalloped implant-abutment connection. There were no significant differences between the two treatment modalities regarding professional or patient-reported outcome measures. Meta-analysis disclosed a mean difference of peri-implant marginal bone loss of 1.56 mm (confidence interval: 0.87 to 2.25), indicating significant more bone loss around implants with a scalloped implant-abutment connection.

Conclusions: A scalloped implant-abutment connection seems to be associated with higher peri-implant marginal bone loss compared to a flat implant-abutment connection. Therefore, the hypothesis of the present systematic review must be rejected. However, further long-term randomized controlled trials assessing implant treatment outcome with the two treatment modalities are needed before definite conclusions can be provided about the beneficial use of implants with a scalloped implant-abutment connection on preservation of the peri-implant marginal bone level.

Keywords: anodontia; dental implants; dental implant-abutment design; dental prosthesis; radiology; randomized controlled trial.

Accepted for publication: 28 March 2017

To cite this article:

Starch-Jensen T, Christensen AE, Lorenzen H.

Scalloped Implant-Abutment Connection Compared to Conventional Flat Implant-Abutment Connection: a Systematic Review and Meta-Analysis

J Oral Maxillofac Res 2017;8(1):e2

URL: <http://www.ejomr.org/JOMR/archives/2017/1/e2/v8n1e2.pdf>

doi: [10.5037/jomr.2017.8102](https://doi.org/10.5037/jomr.2017.8102)

INTRODUCTION

Installation of osseointegrated oral implants is a highly successful treatment of complete, partial or single edentulism [1-4]. Traditionally, the outcome of dental implant treatment has been described using objective success criteria from clinical and radiologic parameters. However, during the last decades, there has been a gradual shift in success criteria from survival of implants towards optimal preservation of soft and hard tissues as well as patient aesthetic demands, especially in the visible aesthetic zone [4-6]. Therefore, the appearance of the peri-implant soft-tissue is critical for successful implant treatment outcome and the criteria for implant success in the aesthetic zone should include the establishment of a soft tissue contour with an intact interproximal papilla and a gingival outline that is harmonious with the gingival profile of the adjacent dentition [7].

The level of the peri-implant marginal bone influences the level of the peri-implant mucosa [7]. Preservation of the height of the peri-implant bone crest is therefore essential for the papilla height and the harmonious integration of the restoration. Various approaches have been described in the literature to prevent the peri-implant marginal bone loss, including platform switching, non-submerged approach, implant design modifications and immediate implant placement. Different implant neck configurations and surface characterization have been associated with reduced peri-implant marginal bone loss as documented in several systematic reviews [8,9]. However, the current literature provides insufficient evidence about the effectiveness of different implant-abutment designs and materials in the stability of the peri-implant tissues [10].

Oral implants have previously been characterised by a flat implant-abutment connection perpendicular to the implant axis. However, the alveolar process normally exhibits a three-dimensional anatomy with a lower bone level facially and lingually as compared with the interproximal areas. The anatomy of the alveolar bone crest can therefore be classified as flat, scalloped, or pronounced scalloped. Implants with a flat implant-abutment connection are suitable for installation within an alveolar process with a flat plateau. However, an implant design with a scalloped implant-abutment connection may be more biological feasible due to a frequent presence of a three-dimensional topography of the alveolar process. It has been suggested that an implant neck with a scalloped implant platform might preserve the proximal marginal bone and improve the biologic and aesthetic

outcome [11-13]. Moreover, an animal study in rabbits has demonstrated enhanced preservation of the peri-implant marginal bone and significantly less crestal bone loss with a microthreaded scalloped implant design compared to a conventional flat implant-abutment connection [14].

The dental implant NobelPerfect (Nobel Biocare, Göteborg, Sweden) has a scalloped implant-abutment connection, which is designed to guide and facilitate interproximal remodelling during healing and to maintain bone height and papillae during functional loading. The implant treatment outcome after installation of NobelPerfect implants has previously been assessed in a non-comparative studies reporting high implant survival rate and preservation of the peri-implant marginal bone level [15,16]. However, comparative human studies assessing different implant neck designs are necessary to prove that the scalloped implant design facilitates interproximal bone remodelling and causes less peri-implant bone loss compared to a flat implant-abutment connection. Therefore, the objective of the present systematic review was to test the hypothesis of no difference in implant treatment outcome after installation of implants with an anatomically designed scalloped implant-abutment connection compared to a flat implant-abutment connection.

MATERIAL AND METHODS

Protocol and registration

The methods of the analysis and inclusion criteria were specified in advance and documented in a protocol. The review was registered in PROSPERO, an international prospective register of systematic reviews.

The protocol can be accessed at:

http://www.crd.york.ac.uk/PROSPERO/display_record.asp?ID=CRD42017057312

Registration number: CRD42017057312.

The present systematic review was conducted in accordance with the Preferred Reporting Items for Systematic Reviews and Meta-Analyses (PRISMA) statement for reporting systematic reviews [17].

Types of publications

The review included studies on humans. Letters, editorials, PhD theses, letters to the editor, case reports, abstracts, technical reports, conference proceedings, animal or *in vitro* studies and literature review papers were excluded.

Types of studies

The review included all human randomized controlled clinical trials and controlled clinical trials comparing the final implant treatment outcome after installation of implants with a scalloped implant-abutment connection compared to a flat implant-abutment connection.

Types of outcome measures

The primary outcome measures are the most important measures for evaluating of the final implant treatment outcome. Secondary outcome measures were also included in the present systematic review as surrogate measures.

The primary outcome measures included:

- Survival of suprastructures. Loss of suprastructure was defined as a total loss because of a mechanical and/or biological complication.
- Survival of implants. Loss of implants was defined as mobility of previously clinically osseointegrated implants and removal of non-mobile implants due to progressive peri-implant marginal bone loss and infection.

In addition, the following secondary outcome measures were assessed:

- Clinical peri-implant soft tissue measurements.
- Radiographic peri-implant marginal bone loss.
- Professional and patient-reported outcome measures.
- Technical and biological complications.

Information sources

The search strategy incorporated examinations of electronic databases, supplemented by a thorough hand-search page by page of relevant journals including “British Journal of Oral and Maxillofacial Surgery“, “Clinical Implant Dentistry and Related Research“, “Clinical Oral Implants Research“, “European Journal of Oral Implantology“, “Implant Dentistry“, “International Journal of Oral and Maxillofacial Implants“, “International Journal of Oral and Maxillofacial Surgery“, “International Journal of Periodontics and Restorative Dentistry“, “International Journal of Prosthodontics“, “Journal of Clinical Periodontology“, “Journal of Dental Research“, “Journal of Oral Implantology“, “Journal of Oral & Maxillofacial Research“, “Journal of Periodontology“, “Journal of Prosthetic Dentistry“, “Journal of Craniofacial Surgery“, “Journal of Cranio-Maxillo-Facial Surgery“, “Journal of Oral and Maxillofacial Surgery“, “Periodontology 2000“,

“Oral and Maxillofacial Surgery“, “Oral Surgery Oral Medicine Oral Pathology Oral Radiology“. The manual search also included the bibliographies of all articles selected for full-text screening as well as previously published reviews relevant for the present systematic review. Two of the reviewers (TSJ and HL) performed the search. Any disagreements were resolved by consensus between the two observers.

Search

A MEDLINE (PubMed), Embase, and Cochrane Library search was conducted. No language or year of publication restriction was applied. The search strategy was performed in collaboration with a librarian and utilized a combination of Medical subject heading (MeSH) and free text terms:

1. exp Dental Implantation/ (18640)
2. exp Dentures/ (42691)
3. ((tooth or teeth* or dental) adj3 implant*).mp. (34344)
4. Dental Abutments/ (7289)
5. Dental Implant-Abutment Design/ (746)
6. abutment*.mp. (11217)
7. 1 or 2 or 3 or 4 or 5 or 6 (72413)
8. (scallop* or flat).mp. (46000)
9. 7 and 8 (298)

Selection of studies

The titles of the identified reports were initially screened. The abstract was assessed when the title indicated that the study was relevant. Full-text analysis was obtained for those with apparent relevance or when the abstract was unavailable. The references of the identified papers were cross-checked for unidentified articles. The study selection was performed by two of the reviewers (TSJ and HL). Any disagreements were resolved by consensus between the two observers.

Study eligibility

The inclusion criteria were developed using the PICOS guidelines (Table 1).

Inclusion criteria

Human studies assessing the final implant treatment outcome after installation of implants with a scalloped implant-abutment connection compared to a flat implant-abutment design were included by addressing the previously described outcome measures.

Table 1. PICOS guidelines

Patient and population (P)	All adult patients (> 18 years) with a missing or non-restorable anterior tooth requiring delayed or immediate implant treatment.
Intervention (I)	Installation of an implant with a scalloped implant-abutment connection.
Comparator or control group (C)	A flat implant-abutment design
Outcomes (O)	Survival of suprastructures, survival of implants, clinical soft tissue measurements, peri-implant marginal bone level, professional and patient-reported outcome measures.
Study design (S)	Human studies, including randomized controlled trials and controlled clinical trials, with the aim of comparing the final implant treatment outcome after installation of implants with an anatomically designed scalloped implant-abutment connection compared to a flat implant-abutment design.
Focused question	Are there any differences in the final implant treatment outcome after installation of oral implants with scalloped implant-abutment connection compared to a flat implant-abutment design?

The review exclusively focused on studies with a minimum of one year observation period after functional loading. In addition, at least 10 patients should be included in the study and the number of inserted implants must be clearly specified.

Exclusion criteria

Uncontrolled clinical trials, studies with insufficient description of the performed numbers of surgical procedures and length of follow-up period were excluded.

Data extraction

Data were extracted by one reviewer (TSJ) according to a data-collection form ensuring systematic recording of the outcome measures. In addition, relevant characteristics of the study were recorded. The corresponding author was contacted by e-mail in the absence of important information or ambiguities.

Data items

The following items were collected from the included articles and arranged in the following fields: patients, time of implant installation, implant platform design, prosthetic solution, time before loading, length of observation period, survival of implants, clinical soft tissue measurements, peri-implant marginal bone level, professional and patient-reported outcome measures.

Assessment of methodological quality

The quality assessment of the included studies was undertaken as part of the data extraction process. A methodological quality rating system was used and the classification of the risk of bias potential for each study was based on the following five criteria:

- Random selection in the population (yes/no).
- Definition of inclusion and exclusion criteria (yes/no).
- Report of losses to follow-up (yes/no).
- Validated measurements (yes/no).
- Statistical analysis (yes/no).

The studies were grouped according to:

- Low risk of bias (plausible bias unlikely to seriously alter the results) if all above-described quality criteria were met.
- Moderate risk of bias (plausible bias that weakens confidence in the results) when one of these criteria were not included.
- High risk of bias (plausible bias that seriously weakens confidence in the results) when two or more criteria were missing.

Assessment of heterogeneity

The significance of any discrepancies in the estimates of the treatment effects of the different studies was assessed by means of Cochran's test for heterogeneity and the I^2 statistic, which describes the percentage total variation across studies that is due to heterogeneity rather than chance. Heterogeneity was considered statistically significant if $P < 0.1$. A rough guide to the interpretation of I^2 given in the Cochrane Handbook is as follows: (1) at 0 - 40% the heterogeneity might not be important, (2) 30 - 60% may represent moderate heterogeneity, (3) 50 - 90% may represent substantial heterogeneity, and (4) 75 - 100% may represent considerable heterogeneity [18].

RESULTS

Study selection

Article review and data extraction were performed according to the PRISMA flow diagram (Figure 1).

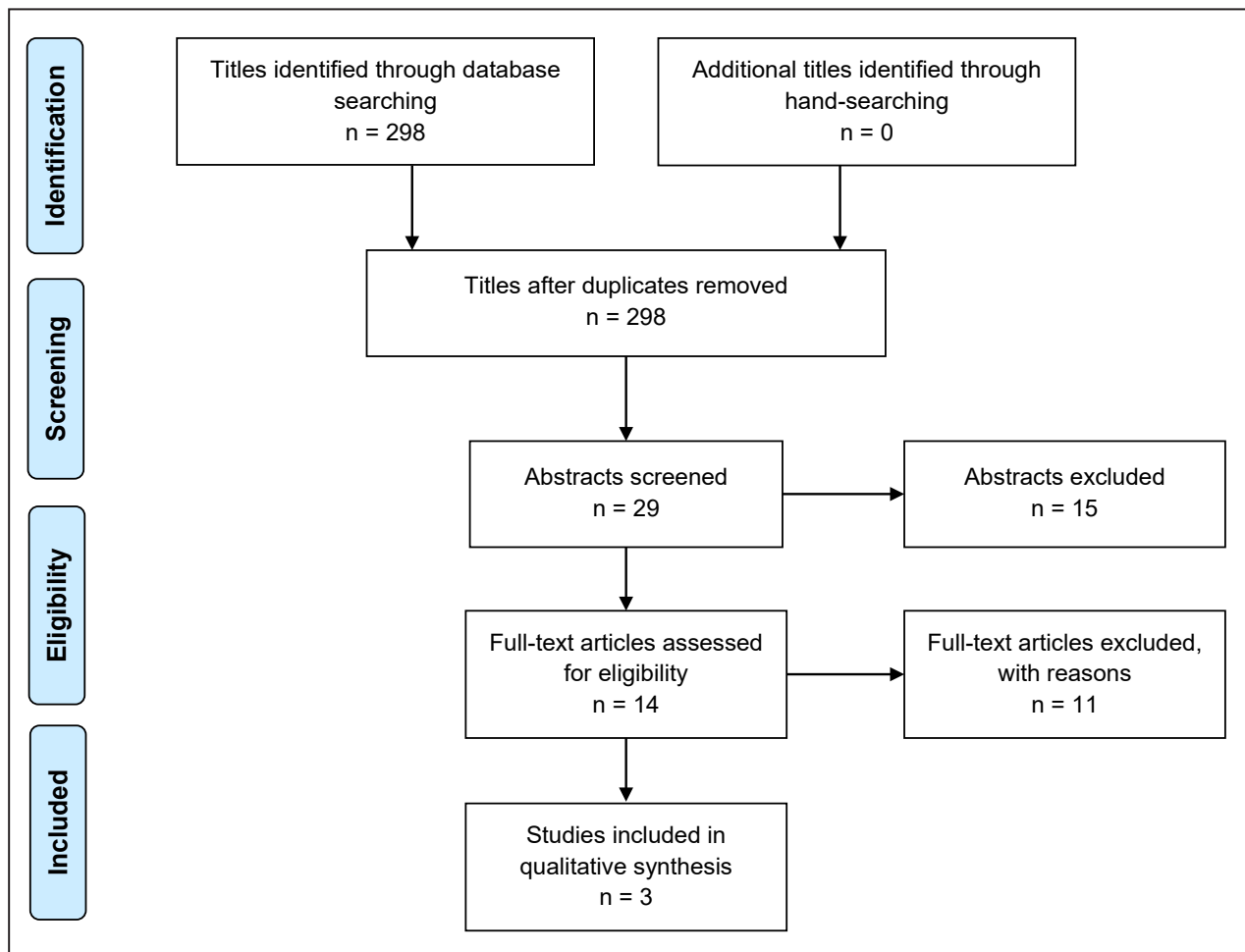


Figure 1. PRISMA flow diagram demonstrating the results of the systematic literature search.

A total of 298 titles were identified and 29 abstracts were reviewed. Full-text analysis included 14 articles and three studies were finally included in the present systematic review [19-21]. No article was included as the result of hand-searching. One study was excluded [22] because the same patient sample with a 5-year observation period was reported in another included publication [21]. Another study was excluded [23], because identical patient sample and outcome measures were reported in another publication [19].

Exclusion of studies

The reasons for excluding studies after full-text assessment were as follows: the study could not be excluded before meticulous reading ($n = 4$), the same patient sample was reported in another publication ($n = 2$), retrospective studies or case-series without a control group ($n = 5$).

Study characteristics

The included studies in the present systematic review consisted of two randomised controlled trials [19,21]

and one prospective controlled trial [20].

Forty patients were allocated to installation of either two adjacent implants with a scalloped implant-abutment connection (NobelPerfect Groovy, Nobel Biocare) or two adjacent implants with a flat implant-abutment connection (NobelReplace Groovy, Nobel Biocare) in the anterior maxilla, in a 5-year randomised clinical trial [21]. Bone augmentation was performed prior to implant installation in approximately half of the patients. Abutment connection and single crowns restorations were fabricated three months after implant installation. Four patients with a scalloped implant-abutment connection and one patient with a flat implant-abutment connection did not participate in the 5-year follow-up examination [21].

Twenty-four patients divided in two groups of 12 implants with a scalloped implant-abutment connection (NobelPerfect, Nobel Biocare) and 12 implants with a flat implant-abutment connection (MK III RP, Nobel Biocare) inserted in the premolar, canine and incisor region in both the maxilla and the mandible, in a 3-year controlled trial [20]. Guided bone regeneration with autogenous bone graft mixed

with Bio-Oss was performed in conjunction with implant installation in 11 patients with a scalloped implant-abutment connection. Abutment connection and single crowns restorations were fabricated six months after implant installation. One patient with a scalloped implant-abutment connection did not participate in the 3-year follow-up examination [20].

Ninety-three patients were allocated to three groups involving installation of 31 implants with a scalloped implant-abutment connection (NobelPerfect, Nobel Biocare), 31 implants with a rough neck and a flat implant-abutment connection (NobelReplace Groovy, Nobel Biocare), and 31 implants with a smooth neck and a flat implant-abutment connection (Replace Select Taperered, Nobel Biocare) inserted in the anterior maxilla, in a 1-year randomised clinical trial [19]. Bone augmentation was performed prior to implant installation in approximately one third of patients. Abutment connection and single crowns restorations were fabricated three months after implant installation. All patients attended the 1-year follow-up examination [19].

The clinical peri-implant soft tissue measurements was assessed in two studies [20,21], involving bleeding score, gingival score, probing depth score, plaque scores, marginal gingiva levels and papilla index.

The radiographic peri-implant marginal bone loss was assessed in three studies [19-21]. Standardized digital intraoral radiographs using the long-cone paralleling technique and specifically designed computer software were used to measure the difference in marginal bone level at implant placement and one year after placement of the definitive crown [19]. Intraoral radiograph and computer software were used to evaluate the marginal bone level at abutment connection, placement of the definitive crown, and 3 months, 6 months, 1 year, and 3 years after placement of the definitive crown [20]. Digital periapical radiographs using a paralleling technique and linear measurements were obtained two weeks after implant placement and 1 months, 1 year, and 5 year after placement of the definitive crown to measure the peri-implant marginal bone level [21].

The professionals perception of the final implant outcome was assessed in two studies [19,21], using the Implant Crown Aesthetic Index. The Pink Esthetic Score (PES) and White Esthetic Score (WES) index were used in one study [19]. The patient-reported outcome measure was assessed in two studies using self-administrated non-validated questionnaire and a visual analogue scale [19,21].

The main results are described below and summarized in Table 2.

Synthesis of results

Meta-analyses were to be conducted only if there were studies of similar comparison, reporting identical outcome measures. However, the studies included revealed considerable variations in study design, i.e. different time frames between implant installation and start of prosthetic loading, implant placement in both the maxilla and the mandible, length of observation period, and type of outcome measures. Therefore, a well-defined meta-analysis was not applicable. However, the difference in peri-implant marginal bone loss across the included studies were analysed including a forest plot. Different implant design and location of the peri-implant marginal bone level measurements were pooled in the flat implant-abutment connection group. The difference in peri-implant marginal bone loss was expressed as mean percentage with a 95% confidence interval (CI).

A fixed effect analysis and test for heterogeneity was performed as well as a random effects model. The mean difference was not standardized, since the included studies used the same unit (mm) and had similar standard deviations. The weights of the studies were calculated using the inverse variance method.

Outcome measures

The result of each outcome measure is presented first and then a short summary is finally provided. Survival of suprastructures, as well as technical and biological complications were not reported in any of the included studies and therefore not presented in the following result section or illustrated in Table 2. All the reported numerical values are presented as mean values with standard deviation (SD) or other characteristics for reported quantitative numeric values.

Primary outcome measures

Survival of implants

The 5-year implant survival rate after delayed implant installation of 40 implants with a scalloped implant-abutment connection was 95% compared to 100% with a flat implant-abutment connection [21]. Twenty patients were treated with two adjacent submerged implants in each group. Two implants with a scalloped implant-abutment connection were lost in the same patient due to severe peri-implantitis after 4 years [21].

The 3-year implant survival rate after delayed implant installation of 12 implants with a scalloped implant-abutment connection or a flat implant-abutment connection was 100%, respectively [20].

Table 2. Included studies assessing scalloped implant-abutment connection compared to flat implant-abutment design

Study	Year of publication	Patient	Materials and methods					Primary outcome measures	Secondary outcome measures						
			Implant	Implant platform design	Prosthetic solution	Time before loading (months)	Length of observation period after loading (months)	Survival of implants	Clinical soft tissue measurements	Peri-implant marginal bone loss Mean (SD) mm	Professional and patient-reported outcome measures Mean (SD)				
			Delayed implant placement								PES	WES	GPS		
den Hartog et al. [19]	2013	93	31	Smooth, flat	Single crown	3	12	96.8%	No significant differences between the groups regarding implant crown aesthetic index or peri-implant mucosa	1.2 (0.8)	6 (1.9)	7.2 (1.5)	8.8 (1.1)		
			31	Rough, flat				100%			0.9 (0.6)	6.3 (1.7)	7.4 (1.6)	8.9 (1)	
			31	Rough, scalloped				100%			2 (0.8) ^b	6.6 (1.6)	7.2 (1.6)	9.1 (0.8)	
Khraisat et al. [20]	2013	24	12	Rough, flat	Single crown	6	36	100%	Soft tissue levels were not maintained around the scalloped implants	Mesial: 1.4 (0.6)	No data				
			12	Smooth, scalloped				100%		Distal: 1.3 (0.7)					
Van Nimwegen et al. [21]	2015	40	40	Rough, flat	Single crown	3	60	100%	Pocket probing depth Mean (SD)	1.5 (0.8)		ICAI	GPS		
			40	Rough, scalloped				FAI					MD	FAT	No significant differences between the groups
								3.8 (1.2)			3 (0.8)		3.2 (1.1)		
							95%	4.9 (2) ^a	4.8 (2.2) ^a	4.7 (2.4) ^a	3.2 (1.1) ^c		8.4 (1.7)		

^aP < 0.001 (Repeated-measures analysis of variance).

^bP < 0.05 (One way analysis of variance).

^cP < 0.001 (Independent t-test).

SD = standard deviation; FAI = facing adjacent implant; FAT = facing adjacent tooth; GPS = general patient satisfaction; ICAI = implant crown aesthetic index; MD = midbuccally; PES = pink aesthetic score; WES = white aesthetic score.

The 1-year implant survival rate after delayed implant installation of 31 implants with a scalloped implant-abutment connection was 100%, 31 implants with a rough neck and a flat implant-abutment connection was 100%, 31 implants with a smooth neck and a flat implant-abutment connection was 96.8%, respectively [19]. There was no statistically significant ($P > 0.05$) difference between the three different treatment modalities.

Summary

High implant survival rate was demonstrated in all the included studies. No statistically significant ($P > 0.05$) difference in implant survival between the different treatment modalities was disclosed.

Secondary outcome measures

Clinical soft tissue measurements

The 5-year clinical assessment of the peri-implant soft tissue demonstrated a significant higher bleeding score, gingival score and probing depth score with a scalloped implant-abutment connection compared to a conventional flat implant-abutment connection [21]. There were no significant differences in plaque score, marginal gingiva level or papilla index between the two treatment modalities, but marginal recession of the peri-implant soft tissue occurred in both groups with no significant differences [21].

The 3-year assessment of the peri-implant soft tissue revealed that the soft tissue levels were not maintained around implants with a scalloped-implant abutment connection with a significant increase over time in papilla index and probing depths [20]. Peri-implant soft tissue measurements were not performed for implants with a flat implant-abutment connection [20].

Summary

Implants with a scalloped implant-abutment connection reveal a significant higher bleeding score, gingival score and probing depth score compared to implants with a flat implant-abutment connection.

Radiographic peri-implant marginal bone loss

The 5-year peri-implant marginal bone loss was significant higher around implants with a scalloped implant-abutment connection (3.2 [1.1] mm) compared to implants with a flat implant-abutment connection (1.5 [0.8] mm). The marginal bone loss facing the adjacent tooth or implant was 3.4 (1) mm

and 3 (1.1) mm with a scalloped implant-abutment connection compared to 1.5 (0.7) mm and 1.4 (0.9) with a flat implant-abutment connection, respectively. The inter-implant bone crest showed a significantly higher marginal bone loss of 2.4 (1) mm a scalloped implant-abutment connection compared to 1.3 (1) mm with a flat implant-abutment connection.

The 3-year peri-implant marginal bone loss measured on the mesial and distal implant side was 3.5 (0.8) mm and 3.5 (1) mm with a scalloped implant-abutment connection compared to 1.4 (0.6) mm and 1.3 (0.7) mm with a flat implant-abutment connection [20]. Implants with a scalloped implant-abutment connection revealed statistically significant ($P < 0.001$) more peri-implant marginal bone loss [20].

The 1-year peri-implant marginal bone was 2 (0.8) mm with a scalloped implant-abutment connection compared to 0.9 (0.6) mm for a flat implant-abutment connection with a rough implant neck and 1.2 (0.8) mm with a flat implant-abutment connection with a smooth implant neck [19]. The scalloped implant-abutment connection showed statistically significant ($P \leq 0.05$) more peri-implant marginal bone loss compared to the other treatment modalities [19].

Summary

Implants with a scalloped implant-abutment connection disclose significantly more peri-implant marginal bone loss compared to implants with a flat implant-abutment design.

Patient-reported outcome measures

The 5-year professional evaluation of the final implant treatment outcome assessed by the Implant Crown Aesthetic Index demonstrated no significant difference between implants with a scalloped implant-abutment connection compared to implants with a flat implant-abutment connection [21]. However, the majority of patients were rated as having poor aesthetics by professionals. The 5-year patient's appreciation of the final implant treatment outcome demonstrated high patient satisfaction with both treatment modalities as evaluated by a visual analogue scale. The mean overall score was 8.4 (1.7) with a scalloped implant-abutment connection compared to 9.1 (0.8) with a flat implant-abutment connection [21]. The 1-year professional evaluation of the final implant treatment outcome assessed by the Implant Crown Aesthetic Index demonstrated no significant difference between implants with a scalloped implant-abutment connection compared to implants with a smooth or rough implant neck

and a flat implant-abutment connection [21]. The PES and WES was 6.6 (1.6) (range 3.5 to 9) and 7.2 (1.6) (range 4.5 to 10) for implants with a scalloped implant-abutment connection compared 6.3 (1.7) (range 3.5 to 9.5) and 7.4 (1.6) (range 4 to 10) for implants with a flat implant-abutment connection with a rough implant neck, and 6 (1.9) (range 1.5 to 9.5) and 7.2 (1.5) (range 4.5 to 9.5) for implants with a flat implant-abutment connection with a smooth implant neck. There was no significant difference in PES and WES between the three treatment modalities [21]. The 1-year patient's appreciation of the final implant treatment outcome demonstrated high patient satisfaction with the three treatment modalities as evaluated by a visual analogue scale. The mean overall score was 9.1 (0.8) for implants with a scalloped implant-abutment connection compared to 8.9 (1) for implants with a flat implant-abutment connection with a rough neck, and 8.8 (1.1) with a flat implant-abutment connection with a smooth neck [19].

Summary

Professional and patient-reported outcome measures reveal high long-term satisfaction with the final implant treatment outcome with no statistically

significant ($P > 0.05$) differences between the different treatment modalities.

Results of meta-analysis

Fixed effect analysis and test for heterogeneity disclosed a considerable heterogeneity among the included studies ($I^2 = 85.9\%$, $P = 0.001$). Therefore, a random effects model was used. Meta-analysis using a random effects demonstrated a mean difference in peri-implant marginal bone loss of 1.56 mm (95% CI = 0.87 to 2.25) between implants with a scalloped implant-abutment connection compared to a flat implant-abutment connection (Figure 2). All the included studies contributed to the mean difference in the same direction, because all the mean difference was greater than zero.

Quality assessment

The quality of the included studies is summarized in Table 3. Two studies were considered low risk of bias [19,21] and one study considered moderate risk of bias [20]. Moreover, clear explanation of withdrawals and drop-outs were included, but blinding of outcome assessment was not performed in any of the included studies.

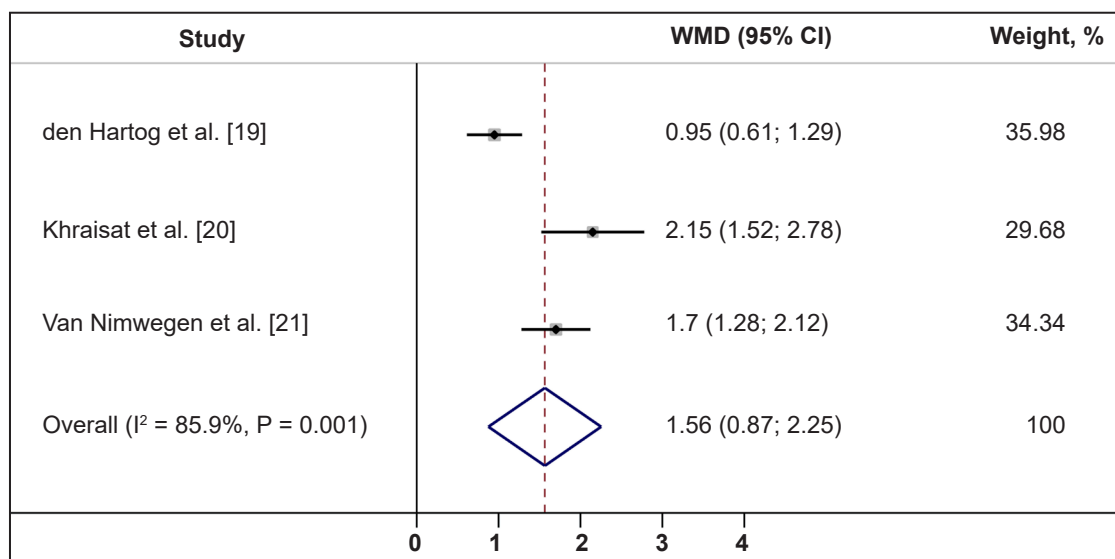


Figure 2. Meta-analysis using a random effects assessing peri-implant marginal bone level. Note: weights are from random effects analysis.

Table 3. Quality assessment of included studies

Study	Random selection in the population	Definition of inclusion and exclusion criteria	Report of losses to follow-up	Validated measurements	Statistical analysis	Risk of bias
den Hartog et al. [19]	Yes	Yes	Yes	Yes	Yes	Low
Khraisat et al. [20]	No	Yes	Yes	Yes	Yes	Moderate
Van Nimwegen et al. [21]	Yes	Yes	Yes	Yes	Yes	Low

DISCUSSION

The current knowledge about implant treatment outcome after installation of implants with a scalloped implant-abutment connection compared to implants with a flat implant-abutment connection was assessed in the present systematic review, including solely randomised controlled clinical trials and controlled clinical trials. A total of two short-term studies [19,20], and one long-term study fulfilled the inclusion criteria [21]. The included studies were characterized by low or moderate risk of bias, but statistical analysis disclosed a considerable heterogeneity among the included studies. Hence, the conclusions drawn from the results of this systematic review should be cautiously interpreted. High implant survival rate after installation of implants with a scalloped implant-abutment connection was disclosed in all the included studies [19-21]. Professional and patient-reported outcome measures reveal high long-term satisfaction with the final implant treatment outcome with no statistically significant ($P > 0.05$) differences between the different treatment modalities, although implants with a scalloped implant-abutment connection demonstrated significant higher peri-implant marginal bone loss, higher probing depth score, bleeding score and gingival score compared to implants with a flat implant-abutment connection.

The primary outcome measures are the most important measures for the assessment of the long-term final implant treatment outcome. However, secondary outcome measures were also included in the present systematic review as surrogate measures. As previously stated, the survival of the suprastructures after installation of implants with a scalloped implant-abutment connection compared to implants with a flat implant-abutment connection has never been compared within the same study.

Placement of oral implants in partially or totally edentulous patients have demonstrated high long-term implant survival rate, as documented in several reviews and long-term studies [1-4]. A systematic review has indicated that, implant loss before functional loading was expected to occur in about 2.5% of all inserted implants and in about 2 - 3% of implants supporting fixed reconstructions during functional loading, while in overdenture therapy more than 5% of the implants can be expected to be lost during a 5-year period [1]. Moreover, a recently published systematic review and meta-analysis indicated an estimated survival of implants supporting fixed dental prostheses of 95.6% after 5 years and 93.1% after 10 years [2]. All the included studies in

the present systematic review demonstrated high implant survival rate and in accordance with these success criteria for implant survival.

Several factors may influence peri-implant marginal bone loss, including smoking, hygiene deficiency, systemic medical conditions, parafunctional habits, different connections between implant and suprastructure, implant neck design and implant surface [24-26]. According to Albrektsson et al. [25] a criterion of a successful implant treatment may include marginal bone loss less than 1 to 1.5 mm during the first year after implant loading and less than 0.2 mm annually, which in turn corresponds to a maximum of 2.3 mm over 5 years and 3.3 mm after 10 years [26]. All of the included studies in this systematic review disclosed a gradually peri-implant marginal bone loss and the 5-year peri-implant marginal bone loss around implants with a scalloped implant-abutment connection was ≥ 3 mm [21]. Moreover, meta-analysis disclosed a mean difference of peri-implant marginal bone loss of 1.56 mm (95% CI = 0.87 to 2.25), between implants with a scalloped implant abutment connection compared to a flat implant-abutment connection. Therefore, implants with a scalloped implant-abutment connection seem to be associated with higher peri-implant marginal bone loss and do not to meet these long-term success criteria. However, the major part of the peri-implant marginal bone loss occurred during the first year after prosthetic loading [21], which is in accordance with previous published studies assessing long-term marginal bone level changes with different implant systems [26,27]. Moreover, no statistically significant differences ($P > 0.05$) in peri-implant marginal bone loss were observed from one year until five years of functional loading between implants with a scalloped implant-abutment connection compared to implants with a flat implant-abutment connection [21]. Therefore, further studies assessing the long-term peri-implant marginal bone loss after installation of implants with a scalloped implant-abutment connection is needed, before definite conclusions can be provided about the beneficial use of a scalloped implant-abutment connection on preservation of the peri-implant marginal bone level.

In recent years, more emphasis in implant dentistry has been concentrated on the appearance of the peri-implant soft-tissue including professional and patient perception of the final aesthetic outcome. The Implant Crown Aesthetic Index, PES and WES, Oral Health Impact Profile Questionnaire, Orofacial Esthetic Scale, and Chewing Function Questionnaire are commonly used methods for assessment of professional and patient-reported outcome measures.

PES and WES are well-established professional indexes for monitoring the long-term aesthetic outcome of the peri-implant soft tissue and the fixed implant restoration [28-30]. The PES index includes the following variables: mesial papilla, distal papilla, level of facial soft tissue margin, soft tissue contour and alveolar process deficiency. The WES index includes the following parameters: form, volume, colour, translucency and surface texture of the crown. The maximum score for both PES and WES is 10 and the threshold of clinical acceptability is 6 [19]. One of the included studies in the present systematic review reported a mean PES of 6.6 (1.6) and WES of 7.2 (1.6), three years after installation implants with a scalloped implant abutment-connection, which is in accordance with the above-mentioned criteria for clinical acceptability [19].

The Implant Crown Aesthetic Index is used to determine the aesthetic of the peri-implant mucosa and the implant crown [31]. The index includes nine items of which five are related to the crown and four are related to the peri-implant mucosa. For each item, penalty points of 0 to 5 can be given as representing no or major deviations compared with the contralateral tooth. The total score for crown and mucosa leads to the following judgment about the final aesthetic outcome: 0 penalty points, excellent; 1 - 2 penalty points, satisfactory; 3 - 4 penalty points, moderate; 5 penalty points or more, poor aesthetic. The Implant Crown Aesthetic Index was used in two of the included studies reporting no significant difference between implants with a scalloped implant-abutment connection compared to implants with a flat implant-abutment connection [19,21].

Patient-reported outcome measures are essentially subjective reports of patients' perceptions of their oral health status and its impact on their daily life or quality of life. The influence of different prosthodontic rehabilitation options on improvement of orofacial aesthetics, chewing function, and oral health-related quality of life is an important prerequisite for selection of the best rehabilitation procedure for the patient with the highest treatment effect and lowest morbidity. A few studies have evaluated the long-term patient-reported outcome measures after installation of oral implants using questionnaires revealing a high degree of patient satisfaction with the treatment outcome [32-34]. These results corroborate the findings of the included studies of the present systematic review [19-21].

Technical and biological complications were not reported in any of the included studies. A published systematic review showed that the most frequent complications over the 5-year observation period were fractures of the veneering material (13.5%), peri-implantitis and soft tissue complications (8.5%), loss of access hole restoration (5.4%), abutment or screw loosening (5.3%), and loss of retention of cemented of fixed dental prostheses (4.7%) [2].

CONCLUSIONS

The hypothesis of no difference in final implant treatment outcome after installation of implants with an anatomically designed scalloped implant-abutment connection compared to a flat implant-abutment connection could neither be confirmed nor rejected due to insufficient evidence. Oral implants with a scalloped implant-abutment connection demonstrated high long-term implant survival rate. However, implants with a scalloped implant-abutment connection disclosed a significantly higher peri-implant marginal bone loss compared to implants with a flat implant-abutment connection. However, the above-mentioned results are solely based on three comparative studies with considerable heterogeneity. Hence, the conclusions drawn from the results of this systematic review should be cautiously interpreted and further long-term randomized controlled trials assessing the final implant treatment outcome with the two treatment modalities are needed before definite conclusions can be provided about the beneficial use of implants with a scalloped implant-abutment connection on preservation of the peri-implant marginal bone level. Therefore, long-term randomized clinical trials assessing the peri-implant marginal bone loss with an observation period of more than five years after installation of implants with a scalloped implant-abutment connection is recommended.

ACKNOWLEDGMENTS AND DISCLOSURE STATEMENTS

The authors declare that there are no financial or other conflicts of interest related to this publication.

REFERENCES

1. Berglundh T, Persson L, Klinge BA. A systematic review of the incidence of biological and technical complications in implant dentistry reported in prospective longitudinal studies of at least 5 years. *J Clin Periodontol*. 2002;29 Suppl 3: 197-212; discussion 232-3. [Medline: [12787220](#)] [doi: [10.1034/j.1600-051X.29.s3.12.x](#)]
2. Pjetursson BE, Thoma D, Jung R, Zwahlen M, Zembic A. A systematic review of the survival and complication rates of implant-supported fixed dental prostheses (FDPs) after a mean observation period of at least 5 years. *Clin Oral Implants Res*. 2012 Oct;23 Suppl 6:22-38. [Medline: [23062125](#)] [doi: [10.1111/j.1600-0501.2012.02546.x](#)]
3. Jung RE, Zembic A, Pjetursson BE, Zwahlen M, Thoma DS. Systematic review of the survival rate and the incidence of biological, technical, and aesthetic complications of single crowns on implants reported in longitudinal studies with a mean follow-up of 5 years. *Clin Oral Implants Res*. 2012 Oct;23 Suppl 6:2-21. [Medline: [23062124](#)] [doi: [10.1111/j.1600-0501.2012.02547.x](#)]
4. Buser D, Sennerby L, De Bruyn H. Modern implant dentistry based on osseointegration: 50 years of progress, current trends and open questions. *Periodontol 2000*. 2017 Feb;73(1):7-21. [Medline: [28000280](#)] [doi: [10.1111/prd.12185](#)]
5. Belser UC, Schmid B, Higginbottom F, Buser D. Outcome analysis of implant restorations located in the anterior maxilla: a review of the recent literature. *Int J Oral Maxillofac Implants*. 2004;19 Suppl:30-42. [Medline: [15635944](#)]
6. Annibali S, Bignozzi I, La Monaca G, Cristalli MP. Usefulness of the aesthetic result as a success criterion for implant therapy: a review. *Clin Implant Dent Relat Res*. 2012 Mar;14(1):3-40. [Medline: [19673953](#)] [doi: [10.1111/j.1708-8208.2009.00234.x](#)]
7. Choquet V, Hermans M, Adriaenssens P, Daelemans P, Tarnow DP, Malevez C. Clinical and radiographic evaluation of the papilla level adjacent to single-tooth dental implants. A retrospective study in the maxillary anterior region. *J Periodontol*. 2001 Oct;72(10):1364-71. [Medline: [11699478](#)] [doi: [10.1902/jop.2001.72.10.1364](#)]
8. de Medeiros RA, Pellizzer EP, Vechiato Filho AJ, Dos Santos DM, da Silva EV, Goiato MC. Evaluation of marginal bone loss of dental implants with internal or external connections and its association with other variables: A systematic review. *J Prosthet Dent*. 2016 Oct;116(4):501-506.e5. [Medline: [27422232](#)] [doi: [10.1016/j.prosdent.2016.03.027](#)]
9. Niu W, Wang P, Zhu S, Liu Z, Ji P. Marginal bone loss around dental implants with and without microthreads in the neck: A systematic review and meta-analysis. *J Prosthet Dent*. 2017 Jan;117(1):34-40. [Medline: [27646798](#)] [doi: [10.1016/j.prosdent.2016.07.003](#)]
10. Bishti S, Strub JR, Att W. Effect of the implant-abutment interface on peri-implant tissues: a systematic review. *Acta Odontol Scand*. 2014 Jan;72(1):13-25. [Medline: [23834528](#)] [doi: [10.3109/00016357.2013.799712](#)]
11. Wöhrle PS. Nobel Perfect esthetic scalloped implant: rationale for a new design. *Clin Implant Dent Relat Res*. 2003; 5 Suppl 1:64-73. [Medline: [12691652](#)] [doi: [10.1111/j.1708-8208.2003.tb00017.x](#)]
12. Kan JY, Rungcharassaeng K, Liddel G, Henry P, Goodacre CJ. Periimplant tissue response following immediate provisional restoration of scalloped implants in the esthetic zone: a one-year pilot prospective multicenter study. *J Prosthet Dent*. 2007 Jun;97(6 Suppl):S109-18. [Medline: [17618925](#)] [doi: [10.1016/S0022-3913\(07\)60014-6](#)]
13. McAllister BS. Scalloped implant designs enhance interproximal bone levels. *Int J Periodontics Restorative Dent*. 2007 Feb;27(1):9-15. [Medline: [17370657](#)]
14. Choi KS, Lozada JL, Kan JY, Lee SH, Kim CS, Kwon TG. Study of an experimental microthreaded scalloped implant design: proximal bone healing at different interimplant distances in a canine model. *Int J Oral Maxillofac Implants*. 2010 Jul-Aug;25(4):681-9. [Medline: [20657862](#)]
15. Paul S, Held U. Immediate supracrestal implant placement with immediate temporization in the anterior dentition: a retrospective study of 31 implants in 26 patients with up to 5.5-years follow-up. *Clin Oral Implants Res*. 2013 Jun;24(6):710-7. [Medline: [22462527](#)] [doi: [10.1111/j.1600-0501.2012.02465.x](#)]
16. Noelken R, Kunkel M, Jung BA, Wagner W. Immediate nonfunctional loading of NobelPerfect implants in the anterior dental arch in private practice--5-year data. *Clin Implant Dent Relat Res*. 2014 Feb;16(1):21-31. [Medline: [22376277](#)] [doi: [10.1111/j.1708-8208.2012.00449.x](#)]
17. Welch V, Petticrew M, Tugwell P, Moher D, O'Neill J, Waters E, White H. PRISMA-Equity Bellagio group. PRISMA-Equity 2012 extension: reporting guidelines for systematic reviews with a focus on health equity. *PLoS Med*. 2012;9(10): e1001333. [Medline: [23222917](#)] [doi: [10.1371/journal.pmed.1001333](#)]
18. Higgins JPT, Green S. *Cochrane Handbook for Systematic Reviews of Interventions* version 5.1.0. The Cochrane Collaboration, 2011. [URL: <http://training.cochrane.org/handbook>]
19. den Hartog L, Raghoobar GM, Slater JJ, Stellingsma K, Vissink A, Meijer HJ. Single-tooth implants with different neck designs: a randomized clinical trial evaluating the aesthetic outcome. *Clin Implant Dent Relat Res*. 2013 Jun;15(3): 311-21. [Medline: [21815991](#)] [doi: [10.1111/j.1708-8208.2011.00372.x](#)]
20. Khraisat A, Zembic A, Jung RE, Hammerle CH. Marginal bone levels and soft tissue conditions around single-tooth implants with a scalloped neck design: results of a prospective 3-year study. *Int J Oral Maxillofac Implants*. 2013 Mar-Apr;28(2):550-5. [Medline: [23527359](#)] [doi: [10.11607/jomi.2544](#)]
21. Van Nimwegen WG, Raghoobar GM, Stellingsma K, Tymstra N, Vissink A, Meijer HJ. Treatment Outcome of Two Adjacent Implant-Supported Restorations with Different Implant Platform Designs in the Esthetic Region: A Five-Year Randomized Clinical Trial. *Int J Prosthodont*. 2015 Sep-Oct;28(5):490-8. [Medline: [26340009](#)] [doi: [10.11607/ijp.4199](#)]

22. Tymstra N, Raghoobar GM, Vissink A, Den Hartog L, Stellingsma K, Meijer HJ. Treatment outcome of two adjacent implant crowns with different implant platform designs in the aesthetic zone: a 1-year randomized clinical trial. *J Clin Periodontol*. 2011 Jan;38(1):74-85. [Medline: [21062337](#)] [doi: [10.1111/j.1600-051X.2010.01638.x](#)]
23. den Hartog L, Meijer HJ, Stegenga B, Tymstra N, Vissink A, Raghoobar GM. Single implants with different neck designs in the aesthetic zone: a randomized clinical trial. *Clin Oral Implants Res*. 2011 Nov;22(11):1289-97. [Medline: [21985286](#)] [doi: [10.1111/j.1600-0501.2010.02109.x](#)]
24. Turri A, Rossetti PH, Canullo L, Grusovin MG, Dahlin C. Prevalence of peri-implantitis in medically compromised patients and smokers: A systematic review. *Int J Oral Maxillofac Implants*. 2016 Jan-Feb;31(1):111-8. [Medline: [26800167](#)] [doi: [10.11607/jomi.4149](#)]
25. Albrektsson T, Zarb G, Worthington P, Eriksson AR. The long-term efficacy of currently used dental implants: a review and proposed criteria of success. *Int J Oral Maxillofac Implants*. 1986 Summer;1(1):11-25. [Medline: [3527955](#)]
26. Laurell L, Lundgren D. Marginal bone level changes at dental implants after 5 years in function: a meta-analysis. *Clin Implant Dent Relat Res*. 2011 Mar;13(1):19-28. [Medline: [19681932](#)] [doi: [10.1111/j.1708-8208.2009.00182.x](#)]
27. Lee SY, Koak JY, Kim SK, Rhyu IC, Ku Y, Heo SJ, Han CH. A Long-Term Prospective Evaluation of Marginal Bone Level Change Around Different Implant Systems. *Int J Oral Maxillofac Implants*. 2016 May-Jun;31(3):657-64. [Medline: [27183075](#)] [doi: [10.11607/jomi.3932](#)]
28. Fürhauser R, Florescu D, Benesch T, Haas R, Mailath G, Watzek G. Evaluation of soft tissue around single-tooth implant crowns: the pink esthetic score. *Clin Oral Implants Res*. 2005 Dec;16(6):639-44. [Medline: [16307569](#)] [doi: [10.1111/j.1600-0501.2005.01193.x](#)]
29. Belser UC, Grütter L, Vailati F, Bornstein MM, Weber HP, Buser D. Outcome evaluation of early placed maxillary anterior single-tooth implants using objective esthetic criteria: a cross-sectional, retrospective study in 45 patients with a 2- to 4-year follow-up using pink and white esthetic scores. *J Periodontol*. 2009 Jan;80(1):140-51. [Medline: [19228100](#)] [doi: [10.1902/jop.2009.080435](#)]
30. Tettamanti S, Millen C, Gavric J, Buser D, Belser UC, Brägger U, Wittneben JG. Esthetic Evaluation of Implant Crowns and Peri-Implant Soft Tissue in the Anterior Maxilla: Comparison and Reproducibility of Three Different Indices. *Clin Implant Dent Relat Res*. 2016 Jun;18(3):517-26. [Medline: [25727214](#)] [doi: [10.1111/cid.12306](#)]
31. Meijer HJ, Stellingsma K, Meijndert L, Raghoobar GM. A new index for rating aesthetics of implant-supported single crowns and adjacent soft tissues--the Implant Crown Aesthetic Index. *Clin Oral Implants Res*. 2005 Dec;16(6):645-9. [Medline: [16307570](#)] [doi: [10.1111/j.1600-0501.2005.01128.x](#)]
32. Pjetursson BE, Karoussis I, Bürgin W, Brägger U, Lang NP. Patients' satisfaction following implant therapy. A 10-year prospective cohort study. *Clin Oral Implants Res*. 2005 Apr;16(2):185-93. [Medline: [15777328](#)] [doi: [10.1111/j.1600-0501.2004.01094.x](#)]
33. Simonis P, Dufour T, Tenenbaum H. Long-term implant survival and success: a 10-16-year follow-up of non-submerged dental implants. *Clin Oral Implants Res* 2010;21:772-7. [Medline: [20636731](#)] [doi: [10.1111/j.1600-0501.2010.01912.x](#)]
34. Derks J, Håkansson J, Wennström JL, Klinge B, Berglundh T. Patient-reported outcomes of dental implant therapy in a large randomly selected sample. *Clin Oral Implants Res*. 2015 May;26(5):586-91. [Medline: [25123298](#)] [doi: [10.1111/clr.12464](#)]

To cite this article:

Starch-Jensen T, Christensen AE, Lorenzen H.

Scalloped Implant-Abutment Connection Compared to Conventional Flat Implant-Abutment Connection: a Systematic Review and Meta-Analysis

J Oral Maxillofac Res 2017;8(1):e2URL: <http://www.ejomr.org/JOMR/archives/2017/1/e2/v8n1e2.pdf>doi: [10.5037/jomr.2017.8102](#)**Copyright** © Starch-Jensen T, Christensen AE, Lorenzen H. Published in the JOURNAL OF ORAL & MAXILLOFACIAL RESEARCH (<http://www.ejomr.org>), 31 March 2017.

This is an open-access article, first published in the JOURNAL OF ORAL & MAXILLOFACIAL RESEARCH, distributed under the terms of the [Creative Commons Attribution-Noncommercial-No Derivative Works 3.0 Unported License](#), which permits unrestricted non-commercial use, distribution, and reproduction in any medium, provided the original work and is properly cited. The copyright, license information and link to the original publication on (<http://www.ejomr.org>) must be included.