

Strontium Ranelate Elevates Expression of Heme Oxygenase-1 and Decreases Alveolar Bone Loss in Rats

Ricardo Basto Souza¹, Francisco Isaac Fernandes Gomes², Karuza Maria Alves Pereira³, Paula Goes Pinheiro Dutra³, Rodrigo Maranguape Silva da Cunha⁴, Hellíada Vasconcelos Chaves², Mirna Marques Bezerra¹

¹Faculty of Medicine, Federal University of Ceará, Sobral, Ceará, Brazil.

²Faculty of Dentistry, Federal University of Ceará, Sobral, Ceará, Brazil.

³Department of Pathology and Legal Medicine, Faculty of Medicine, Federal University of Ceará, Fortaleza, Brazil.

⁴Biotechnology Research Group, Federal University of Ceará and Acaraú Valley State University, Sobral, Ceará, Brazil.

Corresponding Author:

Mirna Marques Bezerra

Faculty of Medicine, Federal University of Ceará-Campus Sobral

62-042-280, Avenida Comandante Maurocélvio Rocha Ponte, 100, Derby, Sobral-CE

Brazil

Phone: 55 88-3611-2202

Fax: 55 88-3611- 8000

E-mail: mirnabrayner@gmail.com

ABSTRACT

Objectives: The purpose of this study was to determine the effects of strontium ranelate on ligature-induced periodontitis in rats and assess the putative involvement of heme oxygenase-1 (HO-1) pathway in these effects.

Material and Methods: Male Wistar rats underwent nylon ligature placement around maxillary molars and were treated (v.o.) with strontium ranelate (20 or 100 mg/kg) for 7 days. After that, rats were euthanized and histomorphometric/histopathological analyses and RT-PCR for HO-1 expression were performed.

Results: Strontium ranelate (20 or 100 mg/kg) prevented bone resorption by 28% and 38%, respectively. Strontium ranelate treatment (100 mg/kg) up-regulated ($P < 0.05$) heme oxygenase-1 mRNA levels in the gingival tissues in comparison to control groups.

Conclusions: Strontium ranelate prevented periodontal bone loss in experimental periodontitis in rats while heme oxygenase-1 mRNA levels increased after treatment.

Keywords: bone resorption; diphosphonates; heme oxygenase; periodontitis.

Accepted for publication: 27 December 2018

To cite this article:

Souza RB, Gomes FIF, Pereira KMA, Dutra PGP, da Cunha RM, Chaves HV, Bezerra MM.

Strontium Ranelate Elevates Expression of Heme Oxygenase-1 and Decreases Alveolar Bone Loss in Rats

J Oral Maxillofac Res 2018;9(4):e4

URL: <http://www.ejomr.org/JOMR/archives/2018/4/e4/v9n4e4.pdf>

doi: [10.5037/jomr.2018.9404](https://doi.org/10.5037/jomr.2018.9404)

INTRODUCTION

Periodontitis leads to bone loss [1]. Its onset mechanisms require investigation, but large amounts of eicosanoids/cytokines are involved [2]. Mechanical treatments are standard approaches, but cannot stop inflammatory responses. Therefore, immunomodulation can attenuate them.

Thus, heme oxygenase (HO) may be involved in this process as it provides a negative feedback signal. HO-1 is inducible by inflammatory stimuli, while the others are constitutively expressed [3,4].

Albeit HO-1 modulates inflammation, its role in periodontitis is unclear. Strontium ranelate (SR) enhances bone growth and reduces bone loss [5]. Thus, since HO-1 appears to regulate bone loss, we aimed to assess whether SR effects depend on the HO-1 pathway.

MATERIAL AND METHODS

Animals

Forty-eight male Wistar rats (180 - 250 g) were housed in a temperature-controlled room under a 12/12 h light/dark cycle and had free access to food and water. Animal numbers were kept to a minimum and efforts were made to minimize animal suffering. The study protocol complied with the European Communities Council Directive (86/609/EEC), the local guidelines on the welfare of experimental animals, and was approved by the local Ethics Committee of the Faculty of Medicine - Federal University of Ceará (protocol number 54/10).

Experimental periodontitis

Periodontitis was reproduced in a rodent model (n = 6) as previously described [2]. These animals were allotted to the following groups:

- Group 1: unchallenged-group receiving vehicle (0.9%, w/v, NaCl);
- Groups 2, 3, 4, and 5: periodontitis-challenged groups receiving vehicle (0.9%, w/v, NaCl), and euthanized at different time points (3, 7, 11 or 14 days);
- Groups 6, 7, and 8: groups of rats treated with SR (20 or 100 mg/kg) or vehicle (0.9%, w/v, NaCl) 1 hour before periodontitis induction, and once a day until euthanasia on day 7.

Rats were anaesthetized with tribromoethanol (Sigma, St Louis, MO, USA) (1 mL/100 g, i.p.), a 3.0-nylon ligature was placed around maxillary left second

molars. The contralateral right side was used as negative control. The unchallenged group (n = 6) included animals that were not subjected to periodontitis. Animals were weighed daily. Three groups of rats (n = 6) were treated (v.o.) with SR (Protos[®] 2g, Les Laboratoires Servier Industrie, 45 520 Gidy, France) (20 or 100 mg/kg) or vehicle (0.9%, w/v, NaCl) 1 hour before periodontitis induction, and once a day until sacrifice on day 7. SR administration occurred at the same time during the experimental days and food was removed 2 hours before treatment to avoid pharmacokinetics interference. On day 7, animals were euthanized under anaesthesia and the maxillae and gingival tissues were excised to assess alveolar bone resorption, and to perform histopathological (haematoxylin and eosin stain) and molecular analyses.

Assessment of periodontal bone loss

Animals were euthanized under anaesthesia on day 7. Maxillae were removed and fixed in 10% neutral formalin. The maxillary halves were prepared for staining with 1% aqueous methylene blue to differentiate the alveolar bone from teeth as the enamel is not stained. The maxillae were then photographed (Sony Cyber-shot Dsc-h2). The obtained image was transferred to the Image J[®] Software (National Institutes of Health, Bethesda, USA). The alveolar bone loss was assessed by the uncovered molars root surface (mm²) on the buccal aspect of the maxillary by subtracting the total area of the left maxillary tooth and bone resorption from the right maxillary tooth area (negative control) [2]. All acquired images were compared with a known area (1 x 1 mm²).

Histopathological analysis

Additional experiments were performed to assess histological parameters. Maxillae were demineralized in 10% EDTA and included in paraffin. Six-micrometres thick sections were obtained and later stained for haematoxylin and eosin stain analysis. The area between the 1st and 2nd right molars was examined under light microscopy (original magnification x100). To evaluate SR effects on the periodontal tissues, histopathological scores (range 0 to 3) were used to assess the periodontal damage as previously described [6].

Heme oxygenase-1 expression

To evaluate the expression of HO-1, the gingival

tissues were excised on days 3, 7, and 11 for quantitative real-time PCR (qRT-PCR). Total RNA was extracted by guanidinium isothiocyanate phenol-chloroform extraction method [7]. Primers were designed by PrimerBlast using a GenBank (National Centre for Biotechnology Information NCBI). Reference sequences of HO-1 (NM_012580.2) to *Rattus norvegicus* are shown in Table 1. Contamination by genomic DNA was avoided by positioning the primers at the exon-exon junction. The application efficiency of all genes was examined in accordance with literature data [8]. qRT-PCR for gene expression was performed using Mastercycler[®] ep realplex4 (Eppendorf AG, Hamburg, Germany), and Power SYBR Green Master Mix[®] (Applied Biosystems, Foster City, CA, USA). Each sample was analysed in total reaction volume 20 µL, consisting of 0.1 µg of cDNA, 10 µL of 2 X SYBR Green Master Mix[®] and 300 nM of forward and reverse primers. Three replicates of each sample were amplified. The E^(ΔΔCt) method was used to calculate both the HO-1 mRNA relative expression levels [9]. The expression level of the glyceraldehyde-3-phosphate dehydrogenase (GAPDH) was the endogenous control (housekeeping).

Analysis of strontium ranelate safety

Body mass, organ weight changes, and creatinine, alanine aminotransferase (AST), and aspartate aminotransferase (ALT) blood levels were evaluated 7 days after SR treatment. Blood samples were obtained from the orbital plexus for biochemical analysis (creatinine, ALT, AST, alkaline phosphatase - Labtest[®], Lagoa Santa, Brazil). After euthanasia, the liver, kidney, and heart were excised and weighed, and any ulcerative lesions were quantified and macroscopically measured.

Statistical analysis

Parametric data were expressed as mean and standard deviation (M [SD]). One-way ANOVA followed by Bonferroni’s test were used to compare means, and Kruskal-Wallis test followed by Dunn’s test was used

to compare medians. The normal distribution of PCR parameters was studied by Lilliefors (Kolmogorov-Smirnov [K-S]) test. Statistical differences determined if P < 0.05.

RESULTS

Effect of strontium ranelate on the alveolar bone loss

The nylon ligature on maxillary second molars caused significant periodontal bone loss, root exposition and furcation in comparison with the unchallenged group. SR-treatment (100 mg/kg) decreased (P < 0.05) bone loss preserving the periodontal architecture when compared with the periodontitis group (Figures 1 and 2).

Histopathological scores

The histopathological analysis depicted inflammatory infiltration, severe cementum breakdown, and periodontal bone loss on day 7. In SR-treated groups (100 mg/kg), less infiltration of inflammatory cells, alveolar process, and cementum maintenance occurred (Table 2 and Figure 3).

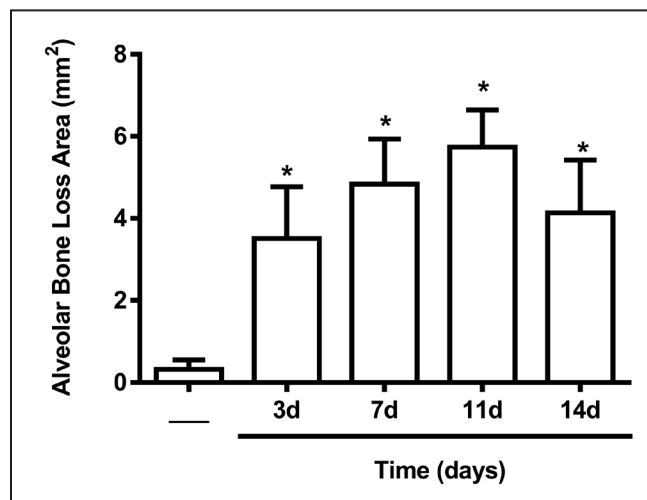


Figure 1. Morphometric analyses of the alveolar bone loss in maxillae until day 14 of periodontitis challenge. *P < 0.05 versus unchallenged group. Data are shown as the mean (SD) for each group of six rats (one-way ANOVA followed by Bonferroni’s test).

Table 1. Category and description of primer sequences from both heme oxygenase-1 (HO-1) and glyceraldehyde-3-phosphate dehydrogenase (GAPDH), according to National Center for Biotechnology Information (NCBI)

| Symbol | Sequence | Access number | Amplicon size | Primer efficiency |
|--------|--|---------------|---------------|-------------------|
| HO-1 | F 5’ ACAGCATACGTAAAGCGTCTCCA-3’ R 5’CATGGCCTTCTGCGCAATCTTCTT-3’ | NM_012580.2 | 136 | 1.974 |
| GAPDH | F 5’-GGGGGCTCTCTGCTCCTCCC-3’ R 5’-CGGCCAAATCCGTTACACCG-3’ | NM_017008.3 | 108 | 1.932 |

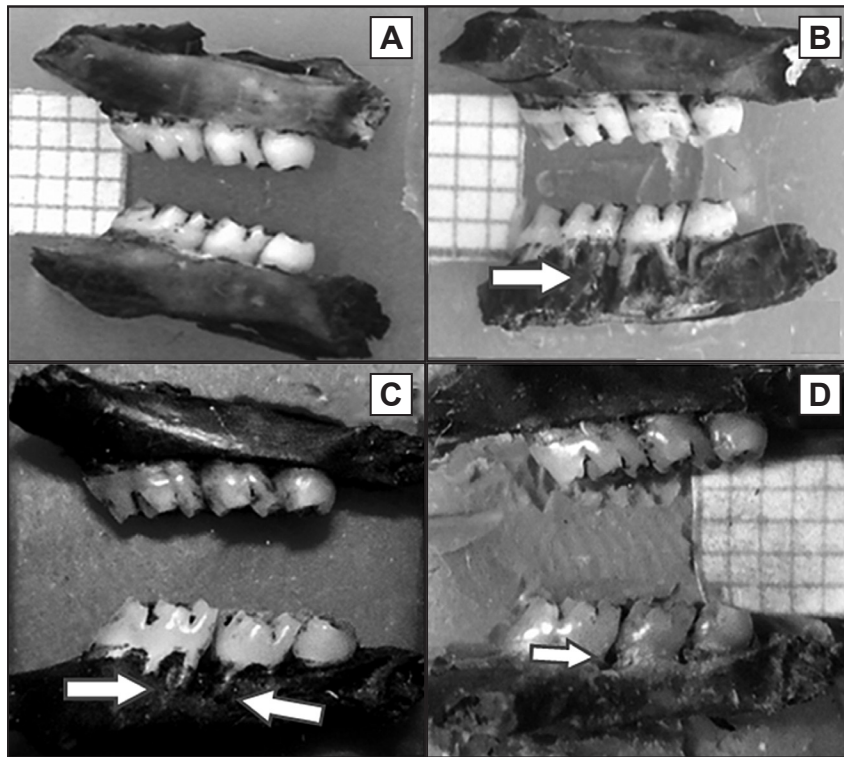


Figure 2. Macroscopic aspect of the hemi-maxillae from rats subjected to periodontitis and treated with strontium ranelate (20 or 100 mg/kg) for 7 days. Upper hemi-maxillae corresponds to the contralateral side used as negative control whilst lower hemi-maxillae corresponds to the following groups: A = maxilla from the unchallenged group; B = maxilla from rats 7 days after periodontitis; C and D = maxilla from strontium ranelate-treated (20 or 100 mg/kg) rats 7 days after periodontitis induction. White arrows indicate the alveolar bone total area in maxillae (1% methylene blue staining).

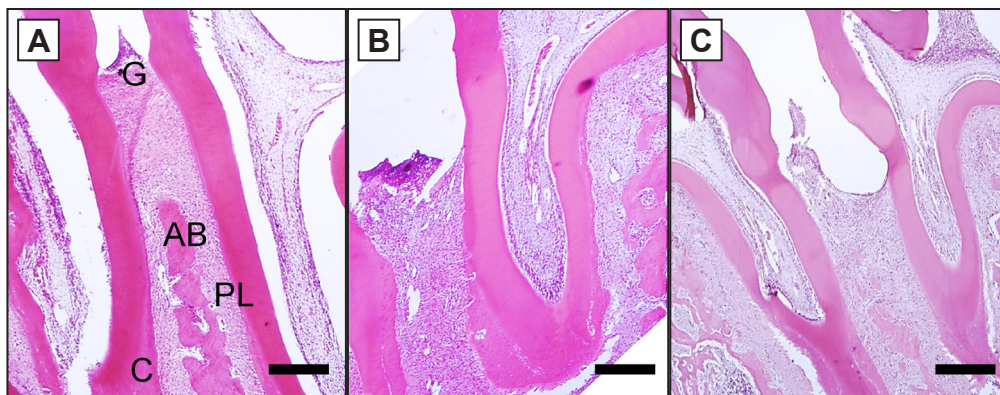


Figure 3. Representative histology of the periodontal tissues: A = rats not subjected to periodontitis (cementum [C], alveolar bone [AB], gingiva [G], and periodontal ligament [PL]); B = maxilla from rats 7 days after periodontitis and not treated; C = treated with strontium ranelate at 100 mg/kg (haematoxylin and eosin stain, original magnification x40).

Table 2. Effect of SR on histopathological analysis of rat maxillae subjected to periodontitis

| Groups | Scores |
|--------|------------------------|
| | Median values (range) |
| Naive | 0 (0 - 0) |
| NT | 3 (2 - 3) ^a |
| SR | 1 (1 - 2) ^b |

^aP < 0.05 compared with the naive group.
^bP < 0.05 compared to NT group.
 Data are reported as median scores (range) for six rats per group (Kruskal-Wallis and Dunn's tests).
 SR = strontium ranelate; NT = non-treated.

Heme oxygenase-1 mRNA expression profile by quantitative real-time PCR

mRNA samples were examined before the cDNA synthesis for purity, integrity, and concentration. The absorbance ratio 260/280 was between 1.8 and 2, which indicates that all samples were proteins or phenol free. Efficiency values obtained for qRT-PCR amplification of three genes were 1.932 (GAPDH) and 1.974 (HO-1), respectively, which indicates that amplification efficiency was near the theoretical optimum level of 2 (Table 1) [9].

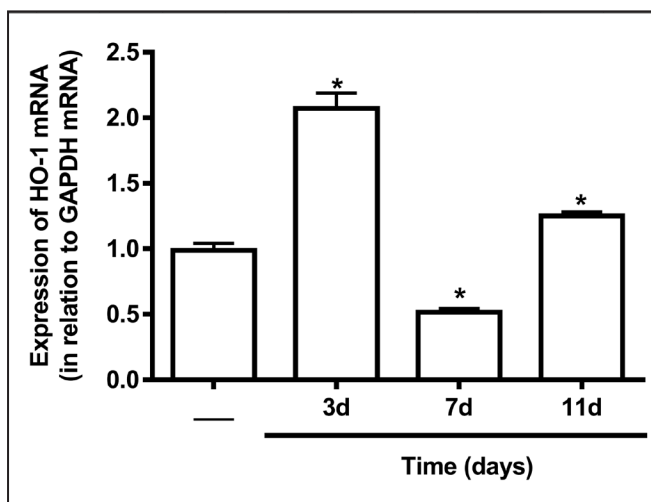


Figure 4. Time-course of HO-1 mRNA expression in gingival tissues after periodontitis challenge. *P < 0.05 versus unchallenged group. Data are shown as the mean (SD) for each group of six rats (one-way ANOVA followed by Bonferroni’s test).

To evaluate the time-course of HO-1 mRNA expression in gingival tissues after periodontitis challenge, rats were euthanized under anaesthesia on days 3, 7, and 11 after periodontitis. The qRT-PCR analysis using on days 3, 7 or 11 revealed that HO-1 mRNA expression achieved its lowest levels on day 7 compared with the unchallenged group (Figure 4). Further, SR (100 mg/kg) up-regulated (P < 0.05) the HO-1 expression levels in the gingival tissues compared with the challenged vehicle-treated group (Figure 5).

Strontium ranelate safety

Repeated administration of SR (100 mg/kg) over 7 consecutive days produced no sign of toxicity. The overall body mass and the wet weights of the liver, kidneys, and heart were normal (not shown). Serum levels of creatinine and enzymatic markers of hepatic function (ALT, AST, and alkaline phosphatase) did not differ from their respective controls (Table 3).

DISCUSSION

This study demonstrated the HO-1 involvement in periodontitis using a rat ligature-induced periodontitis. Some authors showed *in vitro* assays that HO-1 can be a potential target for the treatment of periodontitis [10]. To our knowledge, this is the first report that attempts to identify *in vivo* the participation of HO-1 in periodontitis. Further, our study reported the effects of SR on the alveolar bone loss, finding evidence that SR upregulates HO-1 gene expression in the gingival

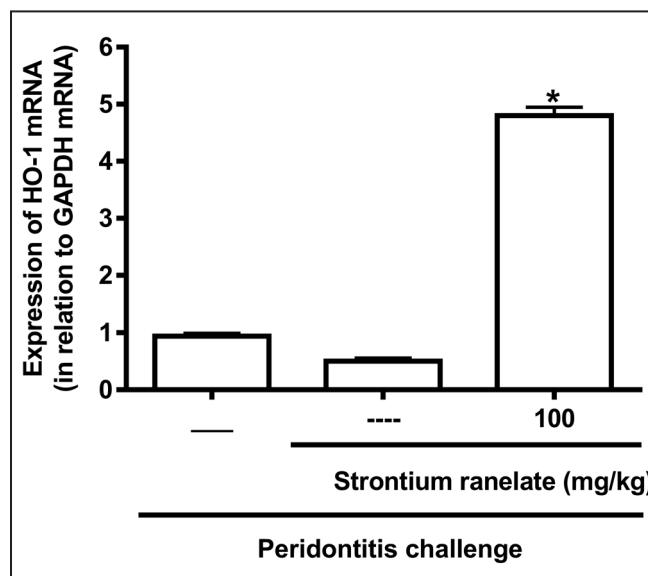


Figure 5. Effects of strontium ranelate on the relative expression of heme oxygenase-1 mRNA levels in gingival tissues. *P < 0.05 versus challenged vehicle-treated group (----). Data are shown as the mean (SD) for each group of six rats (one-way ANOVA followed by Bonferroni’s test).

Table 3. Blood levels of the biochemical parameters of rats subjected to periodontitis and treated with strontium ranelate (SR)

| Parameters | Non-treated | SR (100 mg/kg) |
|----------------------------------|--------------|----------------|
| | Mean (SD) | Mean (SD) |
| Creatinine (mg/dL) | 0.47 (0.03) | 0.55 (0.04) |
| Alanine aminotransferase (U/L) | 134.5 (5.88) | 137.4 (12.6) |
| Aspartate aminotransferase (U/L) | 417.5 (1.56) | 429.5 (29.3) |
| Alkaline phosphatase (U/L) | 417.5 (26.6) | 429.5 (29.3) |

tissues. HO-1 contributes to a proper function of the antioxidant defence system and downregulates cellular activation and production of inflammatory mediators, thus, modulating the inflammatory process [3]. A large amount of studies have reported that the HO-1 expression and its metabolites carbon monoxide and biliverdin exert anti-inflammatory response. In this regard, our research showed that HO-1 inhibition favours inflammatory events [11]. Similarly, HO-1 activation resulted in a reduction of cell migration and pro-inflammatory mediators release [3]. The present study demonstrates that the HO-1 mRNA expression achieved its lowest levels on day 7. It has been shown that alveolar bone loss begins in 3 days after periodontitis induction and reaches maximum levels from days 7 to 11 [2]. Considering the evidence in favour of the HO-1 mediated anti-inflammatory effects, we assume that the alveolar bone loss on days 7 and 11 might be associated with low levels of HO-1 mRNA expression. The literature has also shown a relationship between HO-1 expression and receptor activator of nuclear factor-kappa β ligand

(RANKL)/RANK/osteoprotegerin (OPG) signalling pathway. RANKL/RANK signalling regulates the formation of multinucleated osteoclasts from their precursors as well as their activation and survival in normal bone remodelling and in a variety of pathologic conditions. OPG protects the skeleton from excessive bone resorption by binding to RANKL and preventing it from binding to its receptor, RANK. Thus, RANKL/OPG ratio is an important determinant of bone mass and skeletal integrity [12]. Additionally, this is the first report demonstrating the HO-1 signalling during periodontitis *in vivo*.

SR effectively reduced bone loss, increased bone mass, and bone resistance [13-14]. Albeit the SR mechanism of action is not completely understood, there is evidence showing that it acts on the bone surface, promoting the osteoblastic differentiation via stimulation of calcium sensor receptor, inhibition of osteoclastic differentiation by RANKL suppression, and promotion of osteoprotegerin (OPG) activity. It was also demonstrated that SR can reduce osteoclast numbers in rats with periodontitis [15], which can support the preventing effect of SR on alveolar bone seen in this study.

Our research showed that SR also up-regulated HO-1 mRNA expression in gingival tissues. Several reports demonstrated in murine macrophage-like RAW264.7 cells stimulated with LPS isolated from *Prevotella intermedia* and *Porphyromonas gingivalis* that the anti-inflammatory activity of various promising therapeutic agents in periodontitis occurs via HO-1 expression [16-18].

Phase III trials showed that SR was tolerated, and its safety profile was like that in the youngest participants. Even rarely occurring, SR can induce

drug rash with eosinophilia and systemic symptoms (DRESS) [19]. Herein, we also evaluated the safety of SR administration and observed that SR at 100 mg/kg would be safe when administered to rats over seven consecutive days.

CONCLUSIONS

In summary, the present study demonstrated that the strontium ranelate efficacy in ligature-induced periodontitis in rats is partly dependent on the heme oxygenase-1 up-regulation. Therefore, validating novel therapeutics is very encouraging, broadening our current pharmaceutical choices.

ACKNOWLEDGMENTS AND DISCLOSURE STATEMENTS

The authors thank Adalberto Nascimento de Lima Júnior, Maria Auxiliadora S. Oliveira, Aurilene G. Cajado, Jedson A. de S. Aragão, João G. Alves Filho, Daniel de Brito, Edeline B. Araújo and Ana Patrícia de P. Sudário from Faculty of Dentistry and Medicine - Federal University of Ceará - Sobral for technical assistance, for technical assistance. This work was supported by Brazilian grants from Conselho Nacional de Desenvolvimento Científico e Tecnológico, Coordenação de Aperfeiçoamento de Pessoal de Nível Superior, Instituto de Biomedicina do Semi-Árido Brasileiro, and Fundação Cearense de Apoio ao Desenvolvimento Científico e Tecnológico.

The authors declare that there is no conflict of interests regarding this study.

REFERENCES

1. Ari G, Cherukuri S, Namasivayam A. Epigenetics and Periodontitis: A Contemporary Review. *J Clin Diagn Res.* 2016 Nov;10(11):ZE07-ZE09. [Medline: [28050521](#)] [PMC free article: [5198474](#)] [doi: [10.7860/JCDR/2016/21025.8864](#)]
2. Bezerra MM, de Lima V, Alencar VB, Vieira IB, Brito GA, Ribeiro RA, Rocha FA. Selective cyclooxygenase-2 inhibition prevents alveolar bone loss in experimental periodontitis in rats. *J Periodontol.* 2000 Jun;71(6):1009-14. [Medline: [10914805](#)] [doi: [10.1902/jop.2000.71.6.1009](#)]
3. Alcaraz MJ, Fernández P, Guillén MI. Anti-inflammatory actions of the heme oxygenase-1 pathway. *Curr Pharm Des.* 2003;9(30):2541-51. [Medline: [14529552](#)] [doi: [10.2174/1381612033453749](#)]
4. Oshiro S, Takeuchi H, Matsumoto M, Kurata S. Transcriptional activation of heme oxygenase-1 gene in mouse spleen, liver and kidney cells after treatment with lipopolysaccharide or hemoglobin. *Cell Biol Int.* 1999;23(7):465-74. [Medline: [10728783](#)] [doi: [10.1006/cbir.1999.0375](#)]
5. Cianferotti L, D'Asta F, Brandi ML. A review on strontium ranelate long-term antifracture efficacy in the treatment of postmenopausal osteoporosis. *Ther Adv Musculoskelet Dis.* 2013 Jun;5(3):127-39. [Medline: [23858336](#)] [PMC free article: [3707343](#)] [doi: [10.1177/1759720X13483187](#)]
6. Goes P, Lima AP, Melo IM, Rêgo RO, Lima V. Effect of Atorvastatin in radiographic density on alveolar bone loss in wistar rats. *Braz Dent J.* 2010;21(3):193-8. [Medline: [21203699](#)] [doi: [10.1590/S0103-64402010000300003](#)]
7. Chomczynski P, Sacchi N. Single-step method of RNA isolation by acid guanidinium thiocyanate-phenol-chloroform extraction. *Anal Biochem.* 1987 Apr;162(1):156-9. [Medline: [2440339](#)] [doi: [10.1006/abio.1987.9999](#)]

8. Pfaffl MW, Vandesompele J, Kubista M. Data analysis software. In: J. Logan, K. Edwards, and N. Saunders, editors. *Real-Time PCR: Current Technology and Applications*. Norwich, UK: Caister Academic Press; 2009. p. 65-83.
9. Livak KJ, Schmittgen TD. Analysis of relative gene expression data using real-time quantitative PCR and the 2⁻(Delta Delta C(T)) Method. *Methods*. 2001 Dec;25(4):402-8. [Medline: [11846609](#)] [doi: [10.1006/meth.2001.1262](#)]
10. Pi SH, Jeong GS, Oh HW, Kim YS, Pae HO, Chung HT, Lee SK, Kim EC. Heme oxygenase-1 mediates nicotine- and lipopolysaccharide-induced expression of cyclooxygenase-2 and inducible nitric oxide synthase in human periodontal ligament cells. *J Periodontol Res*. 2010 Apr;45(2):177-83. [Medline: [20470258](#)] [doi: [10.1111/j.1600-0765.2009.01215.x](#)]
11. Grangeiro NM, Aguiar JA, Chaves HV, Silva AA, Lima V, Benevides NM, Brito GA, da Graça JR, Bezerra MM. Heme oxygenase/carbon monoxide-biliverdin pathway may be involved in the antinociceptive activity of etoricoxib, a selective COX-2 inhibitor. *Pharmacol Rep*. 2011;63(1):112-9. [Medline: [21441618](#)] [doi: [10.1016/S1734-1140\(11\)70405-4](#)]
12. Lee HJ, Jeong GS, Pi SH, Lee SI, Bae WJ, Kim SJ, Lee SK, Kim EC. Heme oxygenase-1 protects human periodontal ligament cells against substance P-induced RANKL expression. *J Periodontol Res*. 2010 Jun;45(3):367-74. [Medline: [20337895](#)] [doi: [10.1111/j.1600-0765.2009.01247.x](#)]
13. Ammann P, Shen V, Robin B, Mauras Y, Bonjour JP, Rizzoli R. Strontium ranelate improves bone resistance by increasing bone mass and improving architecture in intact female rats. *J Bone Miner Res*. 2004 Dec;19(12):2012-20. [Medline: [15537445](#)] [doi: [10.1359/jbmr.040906](#)]
14. Reginster JY, Deroisy R, Neuprez A, Hiligsmann M, Zegels B, Bruyere O. Strontium ranelate: new data on fracture prevention and mechanisms of action. *Curr Osteoporos Rep*. 2009 Sep;7(3):96-102. [Medline: [19723468](#)] [doi: [10.1007/s11914-009-0016-1](#)]
15. Karakan NC, Akpınar A, Göze F, Poyraz Ö. Investigating the Effects of Systemically Administered Strontium Ranelate on Alveolar Bone Loss Histomorphometrically and Histopathologically on Experimental Periodontitis in Rats. *J Periodontol*. 2017 Feb;88(2):e24-e31. [Medline: [27615270](#)] [doi: [10.1902/jop.2016.160227](#)]
16. Jin JY, Choi EY, Park HR, Choi JI, Choi IS, Kim SJ. Isorhamnetin inhibits Prevotella intermedia lipopolysaccharide-induced production of interleukin-6 in murine macrophages via anti-inflammatory heme oxygenase-1 induction and inhibition of nuclear factor-κB and signal transducer and activator of transcription 1 activation. *J Periodontol Res*. 2013 Dec;48(6):687-95. [Medline: [23441850](#)] [doi: [10.1111/jre.12054](#)]
17. Park SY, Park DJ, Kim YH, Kim Y, Choi YW, Lee SJ. Schisandra chinensis α-iso-cubebenol induces heme oxygenase-1 expression through PI3K/Akt and Nrf2 signaling and has anti-inflammatory activity in Porphyromonas gingivalis lipopolysaccharide-stimulated macrophages. *Int Immunopharmacol*. 2011 Nov;11(11):1907-15. [Medline: [21840424](#)] [doi: [10.1016/j.intimp.2011.07.023](#)]
18. Er K, Polat ZA, Ozan F, Taşdemir T, Sezer U, Siso SH. Cytotoxicity analysis of strontium ranelate on cultured human periodontal ligament fibroblasts: a preliminary report. *J Formos Med Assoc*. 2008 Aug;107(8):609-15. [Medline: [18678544](#)] [doi: [10.1016/S0929-6646\(08\)60178-3](#)]
19. Cacoub P, Descamps V, Meyer O, Speirs C, Belissa-Mathiot P, Musette P. Drug rash with eosinophilia and systemic symptoms (DRESS) in patients receiving strontium ranelate. *Osteoporos Int*. 2013 May;24(5):1751-7. [Medline: [23361875](#)] [doi: [10.1007/s00198-013-2265-1](#)]

To cite this article:

Souza RB, Gomes FIF, Pereira KMA, Dutra PGP, da Cunha RM, Chaves HV, Bezerra MM.
Strontium Ranelate Elevates Expression of Heme Oxygenase-1 and Decreases Alveolar Bone Loss in Rats
J Oral Maxillofac Res 2018;9(4):e4
URL: <http://www.ejomr.org/JOMR/archives/2018/4/e4/v9n4e4.pdf>
doi: [10.5037/jomr.2018.9404](#)

Copyright © Souza RB, Gomes FIF, Pereira KMA, Dutra PGP, da Cunha RM, Chaves HV, Bezerra MM. Published in the JOURNAL OF ORAL & MAXILLOFACIAL RESEARCH (<http://www.ejomr.org>), 30 December 2018.

This is an open-access article, first published in the JOURNAL OF ORAL & MAXILLOFACIAL RESEARCH, distributed under the terms of the [Creative Commons Attribution-Noncommercial-No Derivative Works 3.0 Unported License](#), which permits unrestricted non-commercial use, distribution, and reproduction in any medium, provided the original work and is properly cited. The copyright, license information and link to the original publication on (<http://www.ejomr.org>) must be included.