

Analysis of the Buccal Bone Plate, Root Inclination and Alveolar Bone Dimensions in the Jawbone. A Descriptive Study Using Cone-Beam Computed Tomography

Joana Gomes dos Santos¹, Ana Paula Oliveira Reis Durão², António Cabral de Campos Felino³, Ricardo Manuel Casaleiro Lobo de Faria de Almeida³

¹Private Practice, Paris, France.

²Porto and Dental Radiology Department of IMAG, Porto, Portugal.

³Department of Medicine and Oral Surgery, University of Porto, Porto, Portugal.

Corresponding Author:

Joana Gomes dos Santos Joana
40 Avenue Raspail, 94250 Gentilly, Île de France
France
Phone: +33 769 055 465
E-mail: joanagsantos.12@gmail.com

ABSTRACT

Objectives: This study aims to determine if there are enough buccal alveolar bone thickness to perform an immediate dental implant placement in anterior and posterior maxillary teeth.

Material and Methods: A total of 1463 teeth were examined, from 202 cone-beam computed tomography scans with voxel sizes of 0.15 mm. On each tooth, the following measures were determined: the alveolar bone thickness in two locations; the vertical distance between the buccal alveolar crest and cemento-enamel junction; the angle between the tooth's long axis and the alveolar bone axial inclination in the sagittal plane.

Results: In the most coronal location of maxillary teeth, the thickness of alveolar bone was lower than 0.6 (SD 0.6) mm in 50% of the teeth, and in the middle of the root the bone thickness was, on average, 0.96 (SD 0.6) mm. For the same maxillary teeth, the vertical distance between the buccal alveolar crest and cemento-enamel junction and the angulation measured were, on average, 3.6 (SD 1.2) mm and 12.1° (SD 1.4°), respectively.

Conclusions: The present study revealed that in most cases the thickness of buccal alveolar bone was less than 1 mm. Consequently, in such cases, immediate dental implant placement operation is not recommended, or should be combined with bone regeneration techniques.

Keywords: alveolar process; cone-beam computed tomography; dental implants; tooth socket.

Accepted for publication: 29 June 2019

To cite this article:

dos Santos JG, Oliveira Reis Durão AP, de Campos Felino AC, Casaleiro Lobo de Faria de Almeida RM.
Analysis of the Buccal Bone Plate, Root Inclination and Alveolar Bone Dimensions in the Jawbone. A Descriptive Study Using Cone-Beam Computed Tomography
J Oral Maxillofac Res 2019;10(2):e4
URL: <http://www.ejomr.org/JOMR/archives/2019/2/e4/v10n2e4.pdf>
doi: [10.5037/jomr.2019.10204](https://doi.org/10.5037/jomr.2019.10204)

INTRODUCTION

Nowadays, immediate implant placement after tooth extraction is performed frequently in clinical practice. However, this technique depends on the thickness and height of the existing buccal cortical bone. After preparing the implant bed, there should be a minimum thickness of 1 mm of buccal cortical bone, and, preferably, a thick gingival biotype in order to guarantee the presence of sufficient gingival tissue and to avoid the buccal bone plate resorption after dental extraction [1-3].

The vertical and horizontal reduction of bone dimensions is inevitable after dental extraction [2,4-7]. The most significant change occurs in the buccal bone plate and the less affected area is the palatal bone plate. Both plates show vertical bone loss or, in other words, a loss in height. The anterior areas are more affected by the resorption of the buccal bone plate than posterior areas, since the resorption is more severe where the walls are initially thinner. According to the literature, the anterior teeth, including the maxillary premolars, have thinner buccal bone plates. In particular, the maxillary incisors and canines show a thinner buccal cortical region than premolars [2,4,6,8-16]. This resorption is more pronounced up to 3 months after dental extraction. However, less intense bone remodelling continues to occur up to 12 months, resulting in dimensional changes [5,6,17].

Paolantonio et al. [18] suggests that immediate implant placement after dental extraction could counter bone crest resorption [18]. However, Araújo et al. [2], and Sanz et al. [9] demonstrated in animal studies, in a dog model, and through clinical trials in humans, respectively, that bone resorption occurs even with immediate implant placement. Therefore, immediate implant placement after dental extraction will not prevent buccal bone plate resorption [2,9,19]. In fact, the degree of resorption will be influenced by the initial thickness of the buccal cortical bone. According to Tomasi et al. [8] and Januário et al. [13], a thinner buccal bone wall will lead to a more serious buccal bone loss [8,13].

In addition to buccal bone thickness, bone resorption is also dependent on the sagittal angle between the tooth's long axis and the axial inclination of the relevant alveolar bone [20]. These conclusions must be taken into consideration before dental extraction and rehabilitation planning, as it might be necessary to use bone regeneration techniques before or during implant placement. For this reason, it is essential to perform a cone-beam computed tomography (CBCT) so that the clinician can select the best approach

and avoid compromising aesthetics in rehabilitation [3,12,13,21-28].

It is essential to understand the morphology and physiological behaviour of the alveolar bone, as well as its average dimensions and inclinations in relation to every type of tooth, in order to choose the appropriate dental implant treatment plan. Thus, the clinician can use a CBCT to predict the existing bone conditions and decide on the best approach. That said, dental extraction should be performed predicting a reduction in the subsequent bone crest. For this reason, several clinical steps should be taken in order to compensate for these changes when considering the replacement of extracted teeth with implants [28].

Studying the bone thickness in all maxillary teeth at a more apical level allows us to investigate if the buccal bone plate thickness in the apical direction can interfere with immediate implant placement. In other words, if there is enough thickness in the buccal bone for implant placement in an anterior maxillary region, as well as in the posterior maxillary region. Nevertheless, the existing studies only include anterior and pre-molar teeth. There is not enough research regarding the first and second molar's buccal bone plates [11-13,21,23-25,29].

In addition to the bone thickness, the distance between the cemento-enamel junction (CEJ) and the bone crest, and the sagittal root position could also be extremely important when deciding the best treatment plan. The distance between the CEJ and the crestal bone will determine the anatomy and morphology of the buccal alveolar crest and, consequently, the position of the gingival margin. Two CBCT studies, Wang et al. [25] and Kim et al. [27], have studied the sagittal relation between the long axis of the tooth and the axial inclination of the respective socket. There is a lack of documented studies on the influence of sagittal root position on treatments plans including immediate or early implants. In fact, the root position could determine the selection of appropriate implant dimensions and its three-dimensional position [25,27]. Therefore, this study's main objective was to determine if there are any differences in the buccal bone plate thickness of the evaluated teeth according to their arch location. The secondary objectives were to determine the distance between the alveolar bone crest and the CEJ and the degree between the tooth's long axis and the alveolar bone axial inclination.

MATERIAL AND METHODS

This study was conducted according to the principles of the Declaration of Helsinki. All patients signed an informed consent form prior to the examination and

treatment. A total of 202 CBCT scans performed in the Diagnostic Centre 3Dxi in Lisbon from January 2017 to December 2017, were selected. The scans were performed for other reasons and not specifically for this study. In the CBCT scans selected for the measurements, information such as age and gender were also collected, but the identities of the patients performing the scans were not disclosed. The collected scans belonged to patients aged between 18 and 73 years old. This study was made in compliance with the STROBE checklist for the cross-sectional studies [30].

Inclusion/exclusion criteria

The study only includes scans with at least one molar and/or one premolar and/or one incisor, with at least one adjacent tooth on the mesial and distal sides of the tooth in assessment; intact maxillary molar teeth regarding buccal roots; intact CEJ in the labial and palatal surfaces of each tooth, and scans with good image definition. The study excluded teeth with infectious pathology, scans from fully edentulous maxillary patients or patients with less than three maxillary teeth, teeth with dehiscence in the buccal bone plate, and scans with poor image definition.

Radiographic analysis

The selected scans were performed with two tools: Cranex 3X[®] and Scanora 3X[®] (Soredex Orion Corporation Ltd, Helsinki, Finland). The size of the field of view was 8 x 8 cm and 8 x 10 cm, and the average resolution (voxel) was 0.15 mm. The term “field of view” refers to the volume of the CBCT scan. Subsequently, the DICOM files were reviewed in a dark room by two observers (JG and RA) with the OnDemand-3D[®] software (Cybermed, Daejeon, Korea) in a 1380 x 800 pixel resolution screen. Whenever required, tools were used to increase and change contrast/brightness in order to improve structure visibility and measurement precision. Each observer measured a maximum of 10 CBCT scans per day.

Measurement protocol

Two observers performed independent measurements for each maxillary tooth which fulfilled the inclusion criteria. The two observers carried out the calibration as follows: 20 scans with a right-hand side canine were randomly selected and all the measurements proposed in this study were performed.

Subsequently, the results obtained by each observer were compared through the intraclass correlation coefficient [14]. The measurements and cut selection were performed in different occasions and the standard deviation was calculated between the two observations. After obtaining a high intraclass correlation coefficient, the observers were ready and trained to start measuring the scans.

These measurements included in each tooth: the measurement of the bone plate thickness in two locations, the measurement of the vertical distance between the buccal bone crest and the CEJ, and the sagittal measurement of the angle between the long axis of the tooth and the alveolar bone axial inclination.

In order to select the appropriate cut for each tooth, the midpoint of the observed distance was determined between the distal and mesial crest of each tooth, in the most coronal point of the bone. The cut was selected on that midpoint. In regards to the maxillary molars, only the mesial-buccal root and the midpoint between the mesial bone crest and the root furcation of the tooth were taken into consideration.

Measurement of the buccal plate thickness

Figure 1 demonstrates how the thickness of the buccal bone plate of each tooth was measured in two different root locations, P1 and P2 [11,25].

Measurement of the distance between the buccal bone crest and CEJ

The facial crestal distance (FCD) is the distance between the most coronal point of the buccal bone crest and the CEJ named [25]. It is illustrated in Figure 2.

Angle measurement between the tooth's long axis and the alveolar bone axial inclination

Figure 3 shows how the angle measurement between the long axis of the tooth and the alveolar bone axial inclination was determined [9,25].

Statistical analysis

The statistical analysis of the data related to this study was conducted through the Statistical Package for the Social Sciences (SPSS) software for Windows, version 20.0 (Chicago, Illinois, USA). Initially, with the objective of describing and characterising the study sample, a descriptive analysis of the data was conducted according to the nature of the studied variables. The statistical inference necessary for

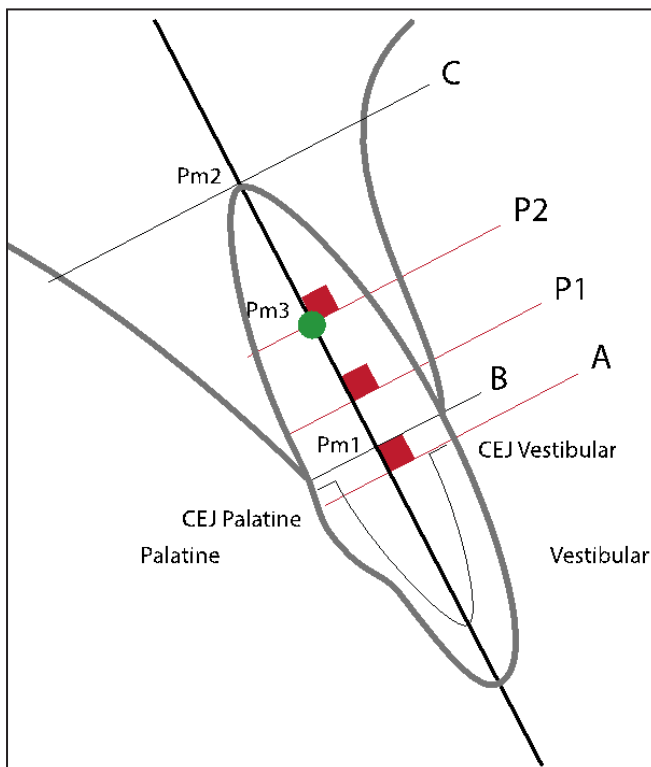


Figure 1. Definition of P1 and P2. The tooth's long axis was used as reference. In order to obtain the mentioned locations, a straight line was drawn intersecting perpendicularly the tooth's long axis and crossing the vestibular CEJ (A). Afterwards, a new straight line was drawn parallel to the previous one, intersecting the tooth's long axis, 4 mm apical to the previous straight line. This new line intersected the buccal bone plate and created P1. In order to obtain P2, the midpoint of the root's length was determined; to do so, a line was drawn joining the palatal and buccal bone crest (B), creating an intersection point with the tooth's long axis (Pm1). In parallel, a straight line was drawn crossing the most apical point in the root apex (C) and intersecting the tooth's long axis (Pm2). Between these two intersections, a midpoint was drawn in the tooth's long axis (Pm3). Lastly, this point was also intersected by a straight line perpendicular to the tooth's long axis and intersecting the buccal bone plate in P2. After establishing the positions, the buccal bone thicknesses were measured, from the root's buccal wall to the external surface of the buccal bone plate. CEJ = cemento enamel junction.

the investigation of the proposed objectives required the implementation of parametric hypothesis tests. In order to compare the mean values between two independent samples, the Kolmogorov-Smirnov test was used to test the sample's normality. The student's t-test was used to determine the variance equality (Levene's test) between samples. Elsewhere, the non-parametric Mann-Whitney test. The parametric ANOVA test was used to compare three or more independent samples. Elsewhere, the non-parametric Kruskal-Wallis test. The results showed that the *Alpha de Cronbach* and ICC coefficients were high, exceeding 0.9 for the first and second collection, confirming a high interobserver and intraobserver reliability, respectively.

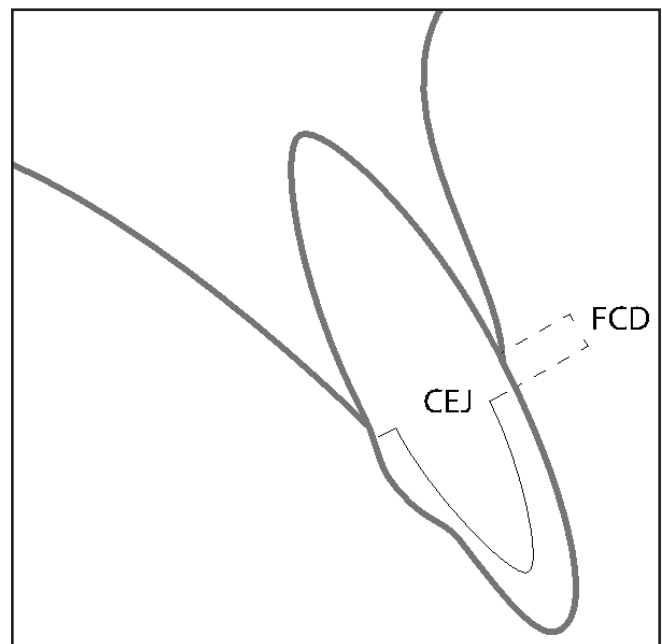


Figure 2. Definition of the facial crestal distance (FCD). CEJ = cemento enamel junction.

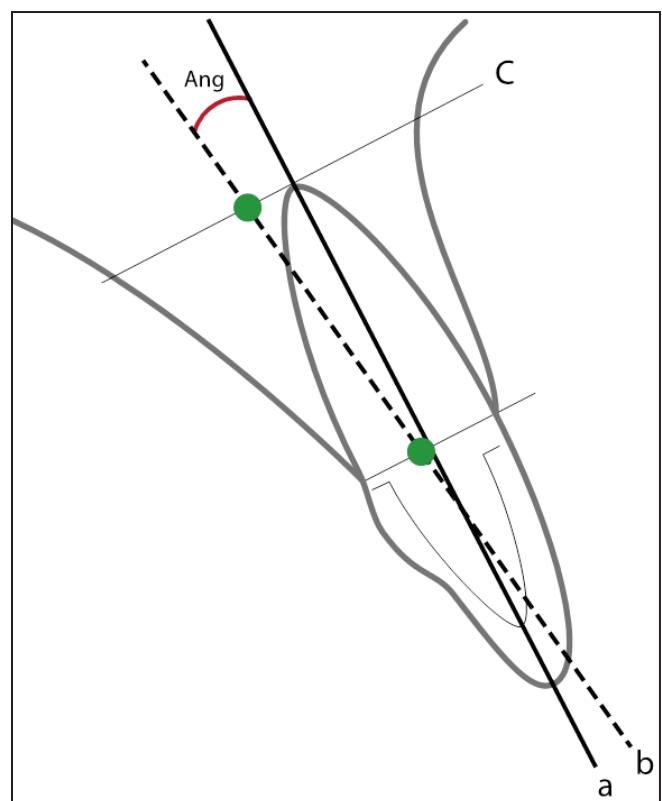


Figure 3. Definition of the tooth's long axis and the alveolar bone axial inclination. The long axis (a) was determined, followed by the alveolar bone axial inclination (b). To determine this axis, a line was drawn joining the palatal and buccal bone crest. Subsequently, the midpoint of this line was determined. In parallel to this line, another line was drawn intersecting the long axis of the tooth, 2 mm apical to the root apex. This line intersected the maxillary bone in the palatal and buccal surfaces and found the midpoint between these points. The alveolar bone axial inclination is a straight line crossing the two midpoints of the two lines. After setting the two axes, the angle (Ang) between them was measured in degrees.

Due to sample size, value categories were set for the variables: bone thickness P1, bone thickness P2, FCD and angle, such as performed in similar studies. Similar to this study, Ghassemian et al. [12], Januário et al. [13], Zekry et al. [21], Nowzari et al. [23] and Wang et al. [25], also distributed the obtained values for the used variables.

The values presented on Tables 1 to 4 are expressed in classes (relative and absolute frequencies), and the Tables 5 and 6 show the values as means and standard deviations (SD). In all statistical tests, a statistical significance level (P-value) was set at $\alpha = 0.05$.

RESULTS

Variables of tooth characterisation according to bone thickness in root location P1 are shown in Table 1. The highest mean value refers to the second molars (1.1 [0.9] mm), followed by the second premolars (0.8 [0.7] mm). Therefore, the lowest values refer to the canines (0.5 [0.5] mm) and to the first premolars (0.4 [0.5] mm).

Table 2 shows the distribution of teeth according to the type of tooth in relation to bone thickness P2.

Table 1. Tooth characterisation according to bone thickness P1

Bone thickness P1	Type of tooth							Total
	Central incisor	Lateral incisor	Canine	First premolar	Second premolar	First molar	Second molar	
	n (%row) %column	n (%row) %column	n (%row) %column	n (%row) %column	n (%row) %column	n (%row) %column	n (%row) %column	
0 mm	88 (17.2%) 29.3%	83 (16.1%) 29.6%	116 (22.4%) 41.3%	86 (16.6%) 54.8%	36 (7%) 29.8%	53 (10.3%) 37.9%	54 (10.4%) 30%	517 (100%) 35.3%
[0.1; 1]	177 (29.3%) 58.2%	134 (22.1%) 47.9%	123 (20.3%) 43.8%	56 (9.3%) 35.7%	35 (5.8%) 28.9%	50 (8.3%) 35.7%	30 (5%) 16.7%	605 (100%) 41.4%
[1; 1.5]	35 (16.1%) 11.5%	47 (21.7%) 16.8%	36 (16.6%) 12.8%	12 (5.5%) 7.6%	30 (13.8%) 24.8%	24 (11.1%) 17.1%	33 (15.2%) 18.3%	217 (100%) 14.8%
[1.5; 2]	3 (3.9%) 1%	12 (15.8%) 4.3%	5 (6.6%) 1.8%	3 (3.9%) 1.9%	13 (17.1%) 10.7%	8 (10.5%) 5.7%	32 (42.1%) 17.8%	76 (100%) 5.2%
[2; 2.5]	0 (0%) 0%	3 (8.1%) 1.1%	1 (2.7%) 0.4%	0 (0%) 0%	7 (18.9%) 5.8%	3 (8.1%) 2.1%	23 (62.2%) 12.8%	37 (100%) 5.2%
[2.5; 3]	0 (0%) 0%	0 (0%) 0%	0 (0%) 0%	0 (0%) 0%	0 (0%) 0%	1 (12.5%) 0.7%	7 (87.5%) 3.9%	8 (100%) 0.5%
≥ 3 mm	0 (0%) 0%	1 (33.3%) 0.4%	0 (0%) 0%	0 (0%) 0%	0 (0%) 0%	1 (33.3%) 0.7%	1 (33.3%) 0.6%	3 (100%) 0.2%
Total	304 (20.8%) 100%	280 (19.1%) 100%	281 (19.2%) 100%	157 (10.7%) 100%	121 (8.3%) 100%	140 (9.6%) 100%	180 (12.3%) 100%	1463 (100%) 100%

Table 2. Tooth characterisation according to bone thickness P2

Bone thickness P2	Type of tooth							Total
	Central incisor	Lateral incisor	Canine	First premolar	Second premolar	First molar	Second molar	
	n (%row) %column	n (%row) %column	n (%row) %column	n (%row) %column	n (%row) %column	n (%row) %column	n (%row) %column	
0 mm	1 (33.3%) 0.3%	0 (0%) 0%	1 (33.3%) 0.4%	0 (0%) 0%	0 (0%) 0%	1 (33.3%) 0.7%	0 (0%) 0%	3 (100%) 0.2%
[0.1; 1]	213 (22.9%) 70.1%	204 (22%) 72.9%	213 (22.9%) 75.8%	106 (11.4%) 67.5%	59 (6.4%) 48.8%	91 (9.8%) 65%	43 (4.6%) 23.9%	929 (100%) 63.5%
[1; 1.5]	77 (23.1%) 25.3%	61 (18.3%) 21.8%	52 (15.6%) 18.5%	39 (11.7%) 24.8%	37 (11.1%) 30.6%	28 (8.4%) 20%	40 (12%) 22.2%	334 (100%) 22.8%
[1.5; 2]	12 (10.4%) 3.9%	12 (10.4%) 4.3%	14 (12.2%) 5%	9 (7.8%) 5.7%	18 (15.7%) 14.9%	10 (8.7%) 7.1%	40 (34.8%) 22.2%	115 (100%) 7.9%
[2; 2.5]	1 (2.1%) 0.3%	2 (4.3%) 0.7%	1 (2.1%) 0.4%	3 (6.4%) 1.9%	7 (14.9%) 5.8%	6 (12.8%) 4.3%	23 (62.2%) 12.8%	47 (100%) 3.2%
[2.5; 3]	0 (0%) 0%	1 (5.3%) 0.4%	0 (0%) 0%	0 (0%) 0%	0 (0%) 0%	2 (10.5%) 1.4%	7 (87.5%) 3.9%	19 (100%) 1.3%
≥ 3 mm	0 (0%) 0%	0 (0%) 0%	0 (0%) 0%	0 (0%) 0%	0 (0%) 0%	2 (12.5%) 1.4%	1 (33.3%) 0.6%	16 (100%) 1.1%
Total	304 (20.8%) 100%	280 (19.1%) 100%	281 (19.2%) 100%	157 (10.7%) 100%	121 (8.3%) 100%	140 (9.6%) 100%	180 (12.3%) 100%	1463 (100%) 100%

Table 3. Tooth characterisation according to facial crestal distance (FCD)

FCD	Type of tooth							Total
	Central incisor	Lateral incisor	Canine	First premolar	Second premolar	First molar	Second molar	
	n (%row) %column	n (%row) %column	n (%row) %column	n (%row) %column	n (%row) %column	n (%row) %column	n (%row) %column	
≤ 1 mm	5 (45.5%) 1.6%	4 (36.4%) 1.4%	0 (0%) 0%	0 (0%) 0%	1 (9.1%) 0.8%	0 (0%) 0%	1 (9.1%) 0%	11 (100%) 0.8%
[1; 3]	104 (25%) 34.2%	88 (21.2%) 31.4%	74 (17.8%) 26.3%	24 (5.8%) 15.3%	40 (9.6%) 33.1%	33 (7.9%) 23.6%	53 (12.7%) 29.4%	416 (100%) 28.4%
[3; 5]	171 (19.1%) 56.3%	169 (18.9%) 60.4%	166 (18.5%) 59.1%	110 (12.3%) 70.1%	69 (7.7%) 57%	97 (10.8%) 69.3%	113 (12.6%) 62.8%	895 (100%) 61.2%
≥ 5 mm	24 (17%) 7.9%	19 (13.5%) 6.8%	41 (29.1%) 14.6%	23 (16.3%) 14.6%	11 (7.8%) 9.1%	10 (7.1%) 7.1%	13 (9.2%) 7.2%	141 (100%) 9.6%
Total	304 (20.8%) 100%	280 (19.1%) 100%	281 (19.2%) 100%	157 (10.7%) 100%	121 (8.3%) 100%	140 (9.6%) 100%	180 (12.3%) 100%	1463 (100%) 100%

Table 4. Tooth characterisation according to angle

Angle	Type of tooth							Total
	Central incisor	Lateral incisor	Canine	First premolar	Second premolar	First molar	Second molar	
	n (%row) %column	n (%row) %column	n (%row) %column	n (%row) %column	n (%row) %column	n (%row) %column	n (%row) %column	
< 0°	0 (0%) 0%	0 (0%) 0%	2 (2%) 0.7%	17 (17%) 10.8%	16 (16%) 13.2%	33 (33%) 23.6%	32 (32%) 17.8%	100 (100%) 6.8%
[0; 10]	109 (28.3%) 35.9%	63 (16.4%) 22.5%	38 (9.9%) 13.5%	16 (4.2%) 10.2%	17 (4.4%) 14%	58 (15.1%) 41.4%	84 (21.8%) 46.7%	385 (100%) 26.3%
[10; 20]	167 (22.2%) 54.9%	168 (22.3%) 60%	170 (22.6%) 60.5%	85 (11.3%) 54.1%	66 (8.8%) 54.5%	40 (5.3%) 28.6%	57 (7.6%) 31.7%	753 (100%) 51.5%
≥ 20°	28 (12.4%) 9.2%	49 (21.8%) 17.5%	71 (31.6%) 25.3%	39 (17.3%) 24.8%	22 (9.8%) 18.2%	9 (4%) 6.4%	7 (3.1%) 3.9%	225 (100%) 15.4%
Total	304 (20.8%) 100%	280 (19.1%) 100%	281 (19.2%) 100%	157 (10.7%) 100%	121 (8.3%) 100%	140 (9.6%) 100%	180 (12.3%) 100%	1463 (100%) 100%

Table 5. Variable characterisation in relation to the age group

Age group	Bone thickness P1	Bone thickness P2	FCD	Angle
	Mean (SD)	Mean (SD)	Mean (SD)	Mean (SD)
Up to 40 years old	0.7 (0.3)	1 (0.2)	3.3 (0.7)	10.6 (3.6)
Between 41 and 50 years old	0.6 (0.4)	0.9 (0.3)	3.7 (0.8)	11.6 (5.6)
Between 51 and 60 years old	0.6 (0.5)	1 (0.4)	3.9 (0.9)	12.4 (4.4)
Over 60 years old	0.4 (0.3)	0.9 (0.3)	4.2 (0.7)	13.9 (6.3)
ANOVA test	ET = 4.772; P = 0.003	ET = 0.161; P = 0.922	ET = 9.788; P = 0.000	ET = 3.679; P = 0.013

FCD = facial crestal distance; SD = standard deviation.

Table 6. Variable characterisation according to the type of tooth

Tooth	Bone thickness P1	Bone thickness P2	FCD	Angle
	Mean (SD)	Mean (SD)	Mean (SD)	Mean (SD)
Central incisor	0.6 (0.4)	0.8 (0.3)	3.4 (1.2)	12.7 (5.4)
Lateral incisor	0.6 (0.5)	0.8 (0.4)	3.4 (1.1)	14.8 (6.5)
Canine	0.5 (0.5)	0.8 (0.4)	3.8 (1.2)	16.5 (7.2)
First premolar	0.4 (0.5)	0.9 (0.4)	4 (1)	12.6 (13.5)
Second premolar	0.8 (0.7)	1.1 (0.5)	3.6 (1.6)	10.9 (12.6)
First molar	0.6 (0.6)	0.9 (0.6)	3.7 (1.1)	4.2 (12.7)
Second molar	1.1 (0.9)	1.7 (0.8)	3.5 (1)	6.5 (10.5)
Kruskal-Wallis test	ET = 105.061; P = 0.000	ET = 233.667; P = 0.000	ET = 51.937; P = 0.000	ET = 250.413; P = 0.000

FCD = facial crestal distance; SD = standard deviation.

It can be observed that 70.1% (n = 213) of central incisors; 72.9% (n = 204) of lateral incisors; 75.8% (n = 213) of canines; 67.5% (n = 106) of first premolars; 48.8% (n = 59) of second premolars; 65% (n = 91) of first molars, and 23.9% (n = 43) of second molars showed a bone thickness between 0.1 and 1 mm.

Variables of the distribution according to the type of tooth in relation to FCD are reported in Table 3. It can be observed that 56.3% (n = 171) of central incisors; 60.4% (n = 169) of lateral incisors; 59.1% (n = 110) of canines; 70.1% (n = 110) of first premolars; 57% (n = 69) of second premolars; 69.3% (n = 97) of first molars, and 62.8% (n = 113) of second molars showed a FCD between 3 and 5 mm.

The distribution of teeth according to the type of tooth in relation to angle between the tooth's long axis and the alveolar bone axial inclination, is reported in Table 4. It can be observed that 10.8% (n = 17) of first premolars; 13.2% (n = 16) of second premolars; 23.6% (n = 33) of first molars, and 17.8% (n = 32) of second molars showed an angle with an amplitude lower than 0°. The amplitude between 10° to 20° stands out in the central incisors, 54.9% (n = 167); lateral incisors, 60% (n = 168); canines, 60.5% (n = 170); first premolars, 54.1% (n = 85), and second premolars, 54.5% (n = 66). In molars the angle amplitude distribution shows higher variability.

Table 5 displays the results obtained for the studied variables in relation to the individual's age group. A higher mean value of bone thickness P1 (0.7 [0.3] mm) occurred in the individuals up to 40 years old and a lower mean value (0.4 [0.3] mm), in the individuals over 60 years. Additionally, it can be observed that the mean values variable reduces with the increase in age. The ANOVA test allowed us to verify the assumptions and to conclude that the results were statistically significant in at least one age group. The various comparisons performed in this study allowed us to conclude that significant differences occurred among individuals up to 40 years old and over 60 years of age.

The highest mean value of bone thickness P2 (1 [0.4] mm), occurred in the individuals between 51 and 60 years old, and the lowest mean value of P2 (0.9 [0.3] mm), occurred in individuals between 41 and 50 years old. The parametric ANOVA test allowed us to conclude that the differences observed are not statistically significant (Table 5).

The mean values of FCD increases with the increase in age. Therefore, the highest mean value (4.2 [0.7] mm), occurred in individuals over 60 years of age, and the lowest mean value (3.3 [0.7] mm), occurred in individuals up to 40 years old. Through the ANOVA test it was concluded that there is at least one group

with statistically significant results. Comparisons allowed us to conclude that the results of individuals up to 40 years old are significantly different than the results of individuals between 51 and 60 years old and individuals over 60 years of age. The results of older individuals are also statistically different when compared to the results of individuals between 41 and 50 years old (Table 5).

It can be observed that angle, on average, increases with age. Therefore, the highest mean value (13.9° [6.3°]), occurred in individuals over 60 years of age, and the lowest mean value (10.6° [3.6°]), occurred in individuals up to 40 years old. The ANOVA test revealed that the differences observed are statistically significant in at least one group. The significant differences occur among individuals up to 40 years old and over 60 years of age (Table 5).

The variables of bone thickness in P1, P2, facial crestal distance and angle characterization in accordance to the type of tooth are reported in Table 6. It is evident that the thickness in P2 showed higher values than the thickness in P1. The mean value of FCD was 3.6 (1.2) mm, where 50% registered a maximum of 3.5 mm, and 25% a result greater than or equal to 4.3 mm. Of the evaluated teeth, 66.9% obtained an angle greater than or equal to 10°, 15.4% got an angle greater than or equal to 20°, and 33.1% obtained an angle of less than 10°.

DISCUSSION

This study used a total of 202 CBCT scans with a sample of 1463 teeth (n = 1463) obtained according to the proposed inclusion criteria, also adapted by other similar studies [3,8,10,12,13,21-23,25,29,31-33]. The clinical history of patients was unknown. For this reason, it was impossible to exclude scans from special patients such as: patients with systemic pathologies, patients taking medicines with bone implications, smokers or patients that have undergone orthodontic treatment. Smokers have a tendency to experience more bone resorption after dental extraction than non-smokers [5,12,34,35], and the orthodontic treatment causes changes in the alveolar bone morphology due to changes in tooth position [36]. In this study, the size of the used voxel (0.15 mm) represents a small size, which is convenient to take more precise measurements since the resolution is high [37-39].

The four-measurement protocol was standardised in order to be replicable among the two observers. Therefore, it was possible to guarantee a greater accuracy inter and intraobservers in determining

each measurement. The buccal bone plate thickness was measured in two locations, P1 and P2, in order to analyse the bone thickness in different locations apical to the crown of the tooth, which could interfere with immediate implant placement. The P1 location is more important than P2 as the bone in the bone crest supports the gingival margin and shapes the alveolar bone. For this reason, the distance between the tooth's CEJ and the buccal bone crest (FCD) also becomes relevant [21,29,40].

The angle formed between the long axis of the tooth and the corresponding alveolar bone axial inclination was measured in each tooth [9]. This measurement is important as the sagittal angle of the alveolar bone and its morphology are important in determining the treatment plan and choosing the size and inclination of the implant. In order to have the best three-dimensional position, the implant angle should be the same as the axis angle of the tooth inside the alveolar bone, except when the original position of the tooth is not, by itself, favourable to optimal rehabilitation. According to Juodzbalyis et al. [41] and his classification system for the maxillary anterior extractions socket the need for palatal angulation in an adequate extraction socket varies till 5° and in compromised cases could varies from 5° to 30° [41]. This will help the clinician to adopt further action in order to achieve this goal, namely, resorting to bone regeneration techniques [25-27].

This study main limitation is the CBCT precision when compared to the direct measurement of the bone crest that results in a more accurate measurement. In this type of study, the thickness gauge is not a feasible method as it can only be used after dental extraction, which does not comply with the proposed methodology. For this reason, the CBCT is a more appropriate method. The CBCT allows for the determination of several measurements in various locations and the existing bone quality. Thus, it is considered the most appropriate and used method in implant surgery planning [10,23,42].

In total, the 202 collected scans resulted in a sample of 1463 teeth. In each scan it was possible to measure, according to the inclusion criteria, an average of 7.2 (3.4) teeth. The anterior teeth evaluated were 304 central incisors, 280 lateral incisors, and 281 canines. The posterior teeth evaluated were 157 first premolars, 121 second premolars, 140 first molars, and the remaining 180 were second molars. A higher representativeness of anterior teeth (central incisors, lateral incisors, and canines) was achieved when compared to premolar or molar teeth.

According to several studies, there are morphological differences in the alveolar bone between the anterior

and posterior teeth. Thus, this study evaluated the alveolar bone of each type of tooth: central incisor, lateral incisor, canine, first/second premolar, and first/second molar [4,6,8,13,14,16,34].

The collected scans belonged to male individuals (45.5%) and female individuals (54.4%). The homogeneity between male and female individuals was obtained in each age group resulting in a good sample representativeness.

The ages varied significantly resulting in high standard deviations. For females, the average age was 50.6% (n = 13.6) and for males it was 52.6% (n = 13.3). The high standard deviation reflects the age dispersion. This makes it harder to extrapolate the results for each age group as bone dimension might be dependent on the age of each individual.

For individuals up to 40 years old, greater thickness was observed in P1 (0.7 [0.3] mm) and lower thickness was observed in individuals over 60 years old (0.4 [0.3] mm). It was possible to determine that with the increase in age the bone thickness in P1 reduces (Table 5). However, this was not the case in P2. The results from Braut et al. [11] confirm this assumption. Braut et al. [11] used a similar methodology to this study: a sagittal cut perpendicular to the bone crest was selected and a point 4 mm apical to the CEJ of each anterior tooth was used to measure, perpendicular to the long axis of the tooth, the existing buccal bone thickness (MP1). Subsequently, another point in the middle of the root was selected to measure, also perpendicular to the long axis of the tooth, the existing buccal bone thickness (MP2). Braut et al. [11] observed a tendency for bone thickness reduction with the increase in age only significant in the bone crest area. This conclusion might be related to the fact that the crest area is the first affected area in the presence of chronic infections or periodontitis [11,25].

On the subject of P1, 76.7% of all assessed teeth showed thicknesses lower than 1 mm and 35.3% did not display buccal bone in P1. By evaluating these figures per class, it is possible to determine that regarding P1, 517 teeth (35%) displayed 0 mm of thickness and 605 teeth (41.4%) had between 0.1 and 1 mm. The remaining teeth displayed thicknesses greater than or equal to 1 mm.

Assessing anterior teeth, it was possible to determine that most teeth displayed a very thin buccal bone thickness (< 1 mm): 87.5% of central incisors, 77.5% of lateral incisors and 85.1% of canines. In particular, bone is non-existent in this location in 29.3% of central incisors, 29.6% of lateral incisors and 41.3% of canines. Bone was rarely found greater than or equal to 1 mm (central incisors: 12.5%;

lateral incisors: 22.6%; canines: 15%), as confirmed in several studies: Huynh-Ba et al. [10], Braut et al. [11], and Ghassemian et al. [12], Januário et al. [13], Nowzari et al. [23], Vera et al. [24]. It was also observed that the thickness in P1 of the first premolar was greater than 1 mm in 9.5% of cases, which represents a low percentage when compared to second premolars (41.3%). The second molar presented more frequently a thickness greater than or equal to 2 mm (12.8%), and 53% of these teeth had a thickness greater than or equal to 1 mm in P1. However, the first molar displays a different behaviour. Approximately 73.6% of the assessed first molars displayed a bone thickness of less than 1 mm, close to the first premolar (90.5%) and anterior teeth (central incisors: 87.5%; lateral incisors: 77.5%; canines: 85.1%). This can be explained by the fact that only a measurement at the mesial-buccal root of the first molar was performed, since the thickness in this area is thinner than the root distal buccal area [43]. Temple et al. [43] confirms the presence of a lower thickness of the buccal bone of the mesial-buccal root in comparison to the distal buccal root. The first molar follows the pattern of the first premolar in what concerns buccal bone thickness. Temple et al. [43] investigated the buccal bone thickness in posterior teeth and measured the bone thickness of each maxillary molar root concluding that the second molar does not follow the same pattern as the first molar showing higher bone availability.

P2's bone thickness was on average 0.9 (0.6) mm, 25% of the examined teeth had on average 0.6 mm of thickness and 50% displayed a thickness greater than or equal to 0.8 mm.

Analyzing P2, it was observed that 63.5% of teeth (929) show a thickness between 0.1 and 1 mm, and 22.83% show a thickness between 1 mm (inclusive) and 1.5 mm. The remaining teeth display greater thickness in this location. These figures allow us to predict that the buccal bone thickness will be greater in P2 than in P1.

The thickness in P2 showed higher values than the thickness in P1 (Table 6). For this reason, it is safe to say that the closer we get to the apical direction, the greater the buccal bone thickness. It was possible to verify that 67.5% of first premolars have a thickness of less than 1 mm, where 1.9% have a thickness greater than or equal to 2 mm. The second premolar, in 51.3% of the cases, has a thickness greater than 1 mm against 32.4% of the first premolars. In other words, a reduction in buccal bone thickness from P1 to P2, from coronal to apical, in the first premolar area is observed. Thus, the bone thickness in the second premolar area appears to be more consistent from coronal to apical, which means it is more

constant than on the first premolar, meeting the results obtained by Shen et al. [32]. These results confirm that in the apical direction, bone availability is not always superior, which disturbs the achievement of implant primary stability and might indicate the need for employing bone regeneration techniques prior to implant placement or using narrow diameter implants (< 3.5 mm) [16,21,28,33,44].

Fenestration (P2 = 0 mm) was found in only 3 types of teeth (central incisor, canine, and first premolar), representing a very low percentage (0.2%) when compared to other studies. Zekry et al. [21] observed a fenestration percentage in anterior teeth between 9.9 and 51.6%, and in posterior teeth between 13.9 and 84.5%. However, it is worth mentioning that this study also includes mandibular teeth. Braut et al. [11] also observed 58.8% of lateral incisors with fenestration. This study also used mandibular teeth. The discrepancy found in the results might be related to the use of a different methodology and voxel. Zekry et al. [21] observed a greater fenestration prevalence 5 mm from the alveolar crest and Braut et al. [11] performed the measurement in the root middle area. The voxels used in the previously mentioned studies were 0.4 mm and 0.126 mm, respectively. Additionally, Braut et al. [11] evaluated only 498 teeth and Zekry et al. [21] evaluated 3618 teeth. However, these studies followed different methodologies [11,21].

In what concerns the FCD (Table 5) the mean values increased with age. In individuals over 60 years old, it was possible to observe a greater distance (4.2 [0.7] mm) between the bone crest and the CEJ than on individuals up to 40 years old (3.3 [0.7] mm), resulting in a statistically significant difference. This result is confirmed by the studies conducted by Zekry et al. [21] and Wang et al. [25].

The mean value obtained for FCD was 3.6 (1.2) mm, where 50% registered a maximum of 3.5 mm, and 25% registered a result greater than or equal to 4.3 mm (Table 6). In a small number of teeth, this distance is less than or equal to 1 mm (0.75%); 28.4% show a distance between 1 mm and 3 mm, and in most teeth, the distance is greater than 3 and less than or equal to 5 mm (61.18%). This result is not in accordance with the studies conducted by Zekry et al. [21] and Wang et al. [25], which reported a maximum FCD variation of up to 4 mm. This difference is related to the use of different methodologies, especially regarding the inclusion and exclusion criteria. Zekry et al. [21] excluded all the analyses with a distance to CEJ greater than 4 mm. In Wang's study the measurements were carried out by only one observer with a 0.3 mm voxel, which is less accurate than the voxel used in this study (0.15 mm)

[21,25]. The studies performed by Januário et al. [13], show that the FCD (between 1 and 2 mm) for central incisors was very different than the values found in our study. In 64.2% of the cases regarding the central incisors and in 73.7% regarding the canines, the FCD obtained was greater than 3 mm. This difference might be explained by the smaller sample used by Januário et al. [13] and the different voxel used in CBCT (0.2 mm), since this study used a 0.15 mm voxel. A larger voxel decreases the measurement precision. Also, age might have influenced this result. Our study includes more individuals over 40 years old (156 adults) when compared to the study performed by Januário et al. [13] (112 adults), which confirms that this measurement tends to increase with age [13,21]. This event is the result of the physiological bone loss that occurs with age, as also confirmed by Ghassemian et al. [12] and Zecry et al. [21].

Of the evaluated teeth, 66.9% obtained an angle greater than or equal to 10°, 15.4% got an angle greater than or equal to 20°, and 33.1% obtained an angle of less than 10°. Negative angles were found in 10.8% of first premolars; 13.2% of second premolars; 23.6% of first molars, and 17.8% of second molars, showing that these teeth were axial proclined. The posterior teeth showed negative angles more frequently (first premolar: 10.8%; second premolar: 13.2%; first molar: 23.6%; second molar: 17.8%). Both the first and second molar showed more frequently an angle between 10° and 20° (10.2% and 14%, respectively).

Regarding the anterior teeth, it was possible to observe that the angle oscillated more frequently between 10° and 20° (central incisor: 54.9%; lateral incisor: 60%; canine: 60.5%). This result is supported by Wang et al. [25], where over 40% of anterior teeth displayed an angle between 10° and 20°. This angle corresponds to a level II in Lau's classification, where 45% of maxillary anterior teeth allow for immediate implant placement, even with a greater level of difficulty. Angle of less than 10% positive on maxillary anterior teeth (central incisors: 35.9%; lateral incisors: 22.5%; canines: 13.5%) occurred less frequently. In this group of teeth, implant insertion is relatively easy, as it can follow the same orientation as the tooth, deviating slightly to palatal, in order to guarantee greater bone thickness and primary stability. In addition, in Wang et al. [25] the existence of an angle of less than 10° was less frequent (10%) [25,45]. The literature has several studies evaluating the bone plate dimensions in anterior teeth (including premolars) through CBCT [11-13,21,23-25,32]. However, the studies focusing also on molar teeth are less frequent (Zecry et al. [21] and Temple et al. [43]).

Since there are few studies including molar teeth, it is difficult to compare our results with other studies. In fact, there are more studies regarding the anterior area as this is more demanding in terms of aesthetics and treatment depending on bone availability. However, the posterior areas do not always have optimal bone availability, especially in terms of bone height in relation to the maxillary sinus. Thus, it is important to use vertical and horizontal bone regeneration techniques. If these techniques cannot be used, short and narrow implants gain more emphasis [11-13,21,23-25,32].

If we consider 1 mm as the minimum value, it is worth mentioning that it is always safer to have a thickness of 2 mm and to ensure the compliance of the implant bed preparation protocol, as it will allow immediate aesthetics and medium to long-term maintenance [46]. The results found in this study show that this thickness rarely occurs. A bone thickness between 2 and 2.5 mm was found only on 8.1% of lateral incisors, 2.7% of canines, and 8.1% of first molars. This thickness is more frequent in second premolars (18.9%) and second molars (62.2%). A thickness of 2 mm was not found in central incisors and first premolars. These results are in accordance with other studies that resorted to CBCT image measurements [11-13,23,24].

The present study indicated that 76.7% of all assessed teeth showed thicknesses of less than 1 mm, and 35.3% did not display buccal bone in P1. Thus, in most cases, the bone thickness is not enough to allow correct immediate implant placement, including posterior teeth. As such, these cases do not comply with the requisites for immediate implant placement. The results obtained are in accordance with the study performed by Januário et al. [13], in which the buccal bone thickness of anterior teeth was investigated. Approximately 85% of locations displayed a thickness of less than 1 mm, and 40% to 60% of evaluated teeth displayed a bone thickness of less than 0.5 mm. In this study, 250 CBCT scans with anterior maxillary teeth were included [13].

CONCLUSIONS

According to this research, more than 1 mm of buccal bone thickness was rarely found in the anterior (central incisors: 12.5%; lateral incisors: 22.5%; canines: 14.9%), first premolar (9.5%) and first molar teeth (9.5%). The tooth type and its location in the maxilla influence bone thickness available for immediate implant insertion. Older individuals present less bone thickness in

the coronal aspect of the dental root than younger individuals. Most of central incisors (64.2%) and canines (73.7%) presented more than 3 mm of distance between cemento-enamel junction and the most coronal point of the buccal alveolar bone.

The angulation between the tooth's long axis and the alveolar bone axial inclination in the sagittal plane was more frequent between 10° and 20° (51.5%) for all maxillary teeth.

ACKNOWLEDGMENTS AND DISCLOSURE STATEMENTS

The authors wish to thank Cybermed (Daejeon, Korea) for providing the DICOM file reading software Ondemand® and to 3Dxi Imaging Clinic for allowing the CBCT scan selection. There was no conflict of interests.

REFERENCES

1. Buser D, Chappuis V, Belser UC, Chen S. Implant placement post extraction in esthetic single tooth sites: when immediate, when early, when late? *Periodontol* 2000. 2017 Feb;73(1):84-102. [Medline: [28000278](#)] [doi: [10.1111/prd.12170](#)]
2. Araújo MG, Lindhe J. Dimensional ridge alterations following tooth extraction. An experimental study in the dog. *J Clin Periodontol*. 2005 Feb;32(2):212-8. [Medline: [15691354](#)] [doi: [10.1111/j.1600-051X.2005.00642.x](#)]
3. Chappuis V, Engel O, Reyes M, Shahim K, Nolte LP, Buser D. Ridge alterations post-extraction in the esthetic zone: a 3D analysis with CBCT. *J Dent Res*. 2013 Dec;92(12 Suppl):195S-201S. [Medline: [24158340](#)] [PMC free article: [3860068](#)] [doi: [10.1177/0022034513506713](#)]
4. Araújo MG, da Silva JCC, de Mendonça AF, Lindhe J. Ridge alterations following grafting of fresh extraction sockets in man. A randomized clinical trial. *Clin Oral Implants Res*. 2015 Apr;26(4):407-412. [Medline: [24621203](#)] [doi: [10.1111/clr.12366](#)]
5. Saldanha JB, Casati MZ, Neto FH, Sallum EA, Nociti FH Jr. Smoking may affect the alveolar process dimensions and radiographic bone density in maxillary extraction sites: a prospective study in humans. *J Oral Maxillofac Surg*. 2006 Sep;64(9):1359-65. [Medline: [16916669](#)] [doi: [10.1016/j.joms.2006.05.021](#)]
6. Schropp L, Wenzel A, Kostopoulos L, Karring T. Bone healing and soft tissue contour changes following single-tooth extraction: a clinical and radiographic 12-month prospective study. *Int J Periodontics Restorative Dent*. 2003 Aug;23(4):313-23. [Medline: [12956475](#)]
7. Rodd HD, Malhotra R, O'Brien CH, Elcock C, Davidson LE, North S. Change in supporting tissue following loss of a permanent maxillary incisor in children. *Dent Traumatol*. 2007 Dec;23(6):328-32. [Medline: [17991231](#)] [doi: [10.1111/j.1600-9657.2006.00466.x](#)]
8. Tomasi C, Sanz M, Cecchinato D, Pjetursson B, Ferrus J, Lang NP, Lindhe J. Bone dimensional variations at implants placed in fresh extraction sockets: a multilevel multivariate analysis. *Clin Oral Implants Res*. 2010 Jan;21(1):30-6. [Medline: [20070744](#)] [doi: [10.1111/j.1600-0501.2009.01848.x](#)]
9. Sanz M, Cecchinato D, Ferrus J, Pjetursson EB, Lang NP, Lindhe J. A prospective, randomized-controlled clinical trial to evaluate bone preservation using implants with different geometry placed into extraction sockets in the maxilla. *Clin Oral Implants Res*. 2010 Jan;21(1):13-21. [Medline: [19922492](#)] [doi: [10.1111/j.1600-0501.2009.01824.x](#)]
10. Huynh-Ba G, Pjetursson BE, Sanz M, Cecchinato D, Ferrus J, Lang NP. Analysis of the socket bone wall dimensions in the upper maxilla in relation to immediate implant placement. *Clin Oral Implants Res*. 2010 Jan;21(1):37-42. [Medline: [20070745](#)] [doi: [10.1111/j.1600-0501.2009.01870.x](#)]
11. Braut V, Bornstein MM, Belser U, Buser D. Thickness of the anterior maxillary facial bone wall—a retrospective radiographic study using cone beam computed tomography. *Int J Periodontics Restorative Dent*. 2011 Apr;31(2):125-31. [Medline: [21491011](#)]
12. Ghassemian M, Nowzari H, Lajolo C, Verdugo F, Pirroni T, D'Addona A. The thickness of facial alveolar bone overlying healthy maxillary anterior teeth. *J Periodontol*. 2012 Feb;83(2):187-97. [Medline: [21692627](#)] [doi: [10.1902/jop.2011.110172](#)]
13. Januário AL, Duarte WR, Barriviera M, Mesti JC, Araújo MG, Lindhe J. Dimension of the facial bone wall in the anterior maxilla: a cone-beam computed tomography study. *Clin Oral Implants Res*. 2011 Oct;22(10):1168-1171. [Medline: [21320168](#)] [doi: [10.1111/j.1600-0501.2010.02086.x](#)]
14. Barone A, Ricci M, Tonelli P, Santini S, Covani U. Tissue changes of extraction sockets in humans: a comparison of spontaneous healing vs. ridge preservation with secondary soft tissue healing. *Clin Oral Implants Res*. 2013 Nov;24(11):1231-7. [Medline: [22784417](#)] [doi: [10.1111/j.1600-0501.2012.02535.x](#)]
15. Fickl S, Schneider D, Zuhr O, Hinze M, Ender A, Jung RE, Hürzeler MB. Dimensional changes of the ridge contour after socket preservation and buccal overbuilding: an animal study. *J Clin Periodontol*. 2009 May;36(5):442-8. [Medline: [19419446](#)] [doi: [10.1111/j.1600-051X.2009.01381.x](#)]
16. Ten Heggeler JM, Slot DE, Van der Weijden GA. Effect of socket preservation therapies following tooth extraction in non-molar regions in humans: a systematic review. *Clin Oral Implants Res*. 2011 Aug;22(8):779-88. [Medline: [21091540](#)] [doi: [10.1111/j.1600-0501.2010.02064.x](#)]

17. Morjaria KR, Wilson R, Palmer RM. Bone healing after tooth extraction with or without an intervention: a systematic review of randomized controlled trials. *Clin Implant Dent Relat Res*. 2014 Feb;16(1):1-20. [Medline: [22405099](#)] [doi: [10.1111/j.1708-8208.2012.00450.x](#)]
18. Paolantonio M, Dolci M, Scarano A, d'Archivio D, di Placido G, Tumini V, Piattelli A. Immediate implantation in fresh extraction sockets. A controlled clinical and histological study in man. *J Periodontol*. 2001 Nov;72(11):1560-71. [Medline: [11759868](#)] [doi: [10.1902/jop.2001.72.11.1560](#)]
19. Araújo MG, Sukekava F, Wennström JL, Lindhe J. Tissue modeling following implant placement in fresh extraction sockets. *Clin Oral Implants Res*. 2006 Dec;17(6):615-24. [Medline: [17092218](#)] [doi: [10.1111/j.1600-0501.2006.01317.x](#)]
20. Misawa M, Lindhe J, Araújo MG. The alveolar process following single-tooth extraction: a study of maxillary incisor and premolar sites in man. *Clin Oral Implants Res*. 2016 Jul;27(7):884-9. [Medline: [26566965](#)] [doi: [10.1111/clr.12710](#)]
21. Zekry A, Wang R, Chau AC, Lang NP. Facial alveolar bone wall width – a cone-beam computed tomography study in Asians. *Clin Oral Implants Res*. 2014 Feb;25(2):194-206. [Medline: [23294441](#)] [doi: [10.1111/clr.12096](#)]
22. López-Jarana P, Díaz-Castro CM, Falcão A, Falcão C, Ríos-Santos JV, Herrero-Climent M. Thickness of the buccal bone wall and root angulation in the maxilla and mandible: an approach to cone beam computed tomography. *BMC Oral Health*. 2018 Nov 21;18(1):194. [Medline: [30463614](#)] [PMC free article: [6249849](#)] [doi: [10.1186/s12903-018-0652-x](#)]
23. Nowzari H, Molayem S, Chiu CH, Rich SK. Cone beam computed tomographic measurement of maxillary central incisors to determine prevalence of facial alveolar bone width ≥ 2 mm. *Clin Implant Dent Relat Res*. 2012 Aug;14(4):595-602. [Medline: [20491811](#)] [doi: [10.1111/j.1708-8208.2010.00287.x](#)]
24. Vera C, De Kok U, Reinhold D, Limpiphipatanakorn P, Yap AK, Tyndall D, Cooper LF. Evaluation of facial alveolar bone dimension of maxillary anterior and premolar teeth: a cone beam computed tomography investigation. *Int J Oral Maxillofac Implants*. 2012 Nov-Dec; 27(6) 1514-9. [Medline: [23189304](#)]
25. Wang HM, Shen JW, Yu MF, Chen XY, Jiang QH, He FM. Analysis of facial bone wall dimensions and sagittal root position in the maxillary esthetic zone: a retrospective study using cone beam computed tomography. *Int J Oral Maxillofac Implants*. 2014 Sep-Oct;29(5):1123-9. [Medline: [25216138](#)] [doi: [10.11607/jomi.3348](#)]
26. Kan JY, Roe P, Rungcharassaeng K, Patel RD, Waki T, Lozada JL, Zimmerman G. Classification of sagittal root position in relation to the anterior maxillary osseous housing for immediate implant placement: a cone beam computed tomography study. *Int J Oral Maxillofac Implants*. 2011 Jul-Aug;26(4):873-6. [Medline: [21841998](#)]
27. Kim JH, Lee JG, Han DH, Kim HJ. Morphometric analysis of the anterior region of the maxillary bone for immediate implant placement using micro-CT. *Clin Anat*. 2011 May;24(4):462-8. [Medline: [21509812](#)] [doi: [10.1002/ca.21101](#)]
28. Chappuis V, Araújo MG, Buser D. Clinical relevance of dimensional bone and soft tissue alterations post-extraction in esthetic sites. *Periodontol 2000*. 2017 Feb;73(1):73-83. [Medline: [28000281](#)] [doi: [10.1111/prd.12167](#)]
29. El Nahass H, N Naiem S. Analysis of the dimensions of the labial bone wall in the anterior maxilla: a cone-beam computed tomography study. *Clin Oral Implants Res*. 2015 Apr;26(4):e57-e61. [Medline: [24450845](#)] [doi: [10.1111/clr.12332](#)]
30. Vandembroucke JP, von Elm E, Altman DG, Gøtzsche PC, Mulrow CD, Pocock SJ, Poole C, Schlesselman JJ, Egger M; STROBE initiative. Strengthening the Reporting of Observational Studies in Epidemiology (STROBE): explanation and elaboration. *Ann Intern Med*. 2007 Oct 16;147(8):W163-94. [Medline: [17938389](#)]
31. Botticelli D, Berglundh T, Lindhe J. Hard-tissue alterations following immediate implant placement in extraction sites. *J Clin Periodontol*. 2004 Oct;31(10):820-8. [Medline: [15367183](#)] [doi: [10.1111/j.1600-051X.2004.00565.x](#)]
32. Shen JW, He FM, Jiang QH, Shan HQ. [Measurement of facial bone wall thickness of maxillary anterior teeth and premolars on cone beam computed tomography images]. *Zhejiang Da Xue Xue Bao Yi Xue Ban*. 2012 May;41(3):234-8. Chinese. [Medline: [22723156](#)]
33. Zhou Z, Chen W, Shen M, Sun C, Li J, Chen N. Cone beam computed tomographic analyses of alveolar bone anatomy at the maxillary anterior region in Chinese adults. *J Biomed Res*. 2014 Nov;28(6):498-505. [Medline: [25469120](#)] [PMC free article: [4250963](#)] [doi: [10.7555/JBR.27.20130002](#)]
34. Lindhe J, Karring T, Araujo M. Anatomy of periodontal tissues. In: Lindhe J, Lang NP, Karring T, editors. *Clinical Periodontology and Implant Dentistry*. 6 ed. Vol.2. Oxford: Blackwell Publishing; 2015. p.3-46.
35. Cosyn J, Cleymaet R, De Bruyn H. Predictors of Alveolar Process Remodeling Following Ridge Preservation in High-Risk Patients. *Clin Implant Dent Relat Res*. 2016 Apr;18(2):226-33. [Medline: [25041378](#)] [doi: [10.1111/cid.12249](#)]
36. Miyama W, Uchida Y, Motoyoshi M, Motozawa K, Kato M, Shimizu N. Cone-beam computed tomographic evaluation of changes in maxillary alveolar bone after orthodontic treatment. *J Oral Sci*. 2018;60(1):147-153. [Medline: [29576575](#)] [doi: [10.2334/josnusd.17-0151](#)]
37. Scarfe WC, Farman AG. What is cone-beam CT and how does it work? *Dent Clin North Am*. 2008 Oct;52(4):707-30, v. [Medline: [18805225](#)] [doi: [10.1016/j.cden.2008.05.005](#)]
38. Menezes CC, Janson G, da Silveira Massaro C, Cambiaghi L, Garib DG. Precision, reproducibility, and accuracy of bone crest level measurements of CBCT cross sections using different resolutions. *Angle Orthod*. 2016 Jul;86(4):535-42. [Medline: [26488463](#)] [doi: [10.2319/040115-214.1](#)]
39. Ludlow JB, Davies-Ludlow LE, Brooks SL, Howerton WB. Dosimetry of 3 CBCT devices for oral and maxillofacial radiology: CB Mercuray, NewTom 3G and i-CAT. *Dentomaxillofac Radiol*. 2006 Jul;35(4):219-26. [Medline: [16798915](#)] [doi: [10.1259/dmfr/14340323](#)]

40. Chen ST, Buser D. Clinical and esthetic outcomes of implants placed in postextraction sites. *Int J Oral Maxillofac Implants*. 2009;24 Suppl:186-217. [Medline: [19885446](#)]
41. Juodzbaly G, Sakavicius D, Wang HL. Classification of extraction sockets based upon soft and hard tissue components. *J Periodontol*. 2008 Mar;79(3):413-24. [Medline: [18315423](#)] [doi: [10.1902/jop.2008.070397](#)]
42. Amid R, Rahimipour K, Namdari M, Kadkhodazadeh M. Comparison of the Efficacy of Digital Caliper and a Newly Designed Digital Bone Gauge for Measurement of Edentulous Alveolar Ridge Width. *J Dent Sch*. 2017 Jun;35(2):78-80. [URL: <http://www.jdentsch.com>]
43. Temple KE, Schoolfield J, Noujeim ME, Huynh-Ba G, Lasho DJ, Mealey BL. A cone beam computed tomography (CBCT) study of buccal plate thickness of the maxillary and mandibular posterior dentition. *Clin Oral Implants Res*. 2016 Sep;27(9):1072-8. [Medline: [26364803](#)] [doi: [10.1111/clr.12688](#)]
44. Saad M, Assaf A, Gerges E. The Use of Narrow Diameter Implants in the Molar Area. *Int J Dent*. 2016;2016:8253090. [Medline: [27293436](#)] [PMC free article: [4879234](#)] [doi: [10.1155/2016/8253090](#)]
45. Lau SL, Chow J, Li W, Chow LK. Classification of maxillary central incisors-implications for immediate implant in the esthetic zone. *J Oral Maxillofac Surg*. 2011 Jan;69(1):142-53. [Medline: [21050638](#)] [doi: [10.1016/j.joms.2010.07.074](#)]
46. Buser D, Martin W, Belser UC. Optimizing esthetics for implant restorations in the anterior maxilla: anatomic and surgical considerations. *Int J Oral Maxillofac Implants*. 2004;19 Suppl:43-61. [Medline: [15635945](#)]

To cite this article:

dos Santos JG, Oliveira Reis Durão AP, de Campos Felino AC, Casaleiro Lobo de Faria de Almeida RM. Analysis of the Buccal Bone Plate, Root Inclination and Alveolar Bone Dimensions in the Jawbone. A Descriptive Study Using Cone-Beam Computed Tomography
J Oral Maxillofac Res 2019;10(2):e4
URL: <http://www.ejomr.org/JOMR/archives/2019/2/e4/v10n2e4.pdf>
doi: [10.5037/jomr.2019.10204](#)

Copyright © dos Santos JG, Oliveira Reis Durão AP, de Campos Felino AC, Casaleiro Lobo de Faria de Almeida RM. Published in the JOURNAL OF ORAL & MAXILLOFACIAL RESEARCH (<http://www.ejomr.org>), 30 June 2019.

This is an open-access article, first published in the JOURNAL OF ORAL & MAXILLOFACIAL RESEARCH, distributed under the terms of the [Creative Commons Attribution-Noncommercial-No Derivative Works 3.0 Unported License](#), which permits unrestricted non-commercial use, distribution, and reproduction in any medium, provided the original work and is properly cited. The copyright, license information and link to the original publication on (<http://www.ejomr.org>) must be included.