

Lateral Alveolar Ridge Augmentation with an Autogenous Bone Block Graft Alone with or without Barrier Membrane Coverage: a Systematic Review and Meta-Analysis

Romario Gorgis¹, Lianna Qazo², Niels Henrik Bruun³, Thomas Starch-Jensen⁴

¹Department of Oral and Maxillofacial Surgery, Aarhus University Hospital, Aarhus, Denmark.

²Private practice, Denmark.

³Unit of Clinical Biostatistics, Aalborg University Hospital, Aalborg, Denmark.

⁴Department of Oral and Maxillofacial Surgery, Aalborg University Hospital, Aalborg, Denmark.

Corresponding Author:

Romario Gorgis

Palle Juul-Jensens Boulevard 165, 8200, Aarhus

Denmark

Phone: +45 21853253

E-mail: Romgor@rm.dk

ABSTRACT

Objectives: To test the hypothesis of no difference in implant treatment outcome following lateral alveolar ridge augmentation with autogenous bone block graft with or without barrier membrane coverage.

Material and Methods: PubMed (MEDLINE), Embase and Cochrane library search in combination with a hand-search of relevant journals was conducted. Human studies published in English until the 8th of February 2021 were included. Randomised controlled trials with an observation period longer than three months were included. Survival of implants and suprastructures were considered as primary outcomes measures, whereas peri-implant marginal bone loss, dimensional changes of the alveolar ridge, bone regeneration, patient-reported outcome measures, biological and mechanical complications were secondary outcome measures, as evaluated by descriptive statistics and meta-analysis including 95% confidence interval (CI).

Results: Electronic search and hand-searching resulted in 411 entries. Five randomised controlled trials characterised by low or high risk of bias fulfilled inclusion criteria. No statistically significant difference between the two treatment modalities was observed in any of the outcome measures. However, barrier membrane coverage was associated with a non-significant gain in alveolar ridge width of 0.5 mm (95% CI = -0.1 to 1.1) and diminished resorption of -0.9 mm (95% CI = -2.4 to 0.7) compared with no barrier membrane coverage.

Conclusions: Comparable implant treatment outcomes were revealed following lateral alveolar ridge augmentation with autogenous bone block graft alone with or without barrier membrane coverage. However, postoperative dimensional changes of the augmented seems to be diminished with the use of barrier membrane coverage as evaluated by two-dimensional linear measurements.

Keywords: alveolar ridge augmentation; dental implants; membranes; oral surgical procedures; review.

Accepted for publication: 30 September 2021

To cite this article:

Gorgis R, Qazo L, Bruun NH, Starch-Jensen T.

Lateral Alveolar Ridge Augmentation with an Autogenous Bone Block Graft Alone with or without Barrier Membrane Coverage: a Systematic Review and Meta-Analysis

J Oral Maxillofac Res 2021;12(3):e1

URL: <http://www.ejomr.org/JOMR/archives/2021/3/e1/v12n3e1.pdf>

doi: [10.5037/jomr.2021.12301](https://doi.org/10.5037/jomr.2021.12301)

INTRODUCTION

Placement of dental implants in an optimal prosthetically position is frequently compromised or impossible due to dimensional changes of the alveolar ridge following tooth extraction [1-3]. Alveolar ridge augmentation prior to or in conjunction with implant placement is therefore often necessary when the horizontal or vertical dimensions of the alveolar process are inadequate [4-7]. Lateral alveolar ridge augmentation (LARA) with the use of an autogenous bone block graft is the most commonly applied surgical technique to obtain sufficient height and width of the alveolar ridge prior to implant placement [3,7-10]. High implant survival rate and limited peri-implant marginal bone loss (PIMBL) have been reported in long-term studies and systematic reviews following LARA [3,7-10]. However, the use of autogenous bone block graft from extraoral or intraoral donor sites are commonly associated with an unpredictable resorption of the augmented area, which frequently necessitates additional augmentation of the alveolar ridge in conjunction with delayed implant placement [7,11-16]. The autogenous bone block graft is therefore often covered by a non-resorbable bone substitute and shielded by a barrier membrane to stabilize the grafting material and diminish graft resorption [4,16-19]. Various resorbable or non-resorbable membranes composed of biocompatible xenogeneic or synthetic material have previously been used in conjunction with LARA to preserve the initial dimension of augmented area and facilitates incorporation of the autogenous bone block graft [20,21]. However, well-defined implications and benefits for using resorbable or non-resorbable barrier membranes in conjunction with LARA have never previously been determined. The various types of xenogeneic or synthetic barrier membrane contain dissimilar material properties which are intended to improve bone regeneration and hamper soft tissue interference [22,23]. Nevertheless, barrier membrane coverage of the augmented area is associated with lower vascular supply to the applied grafting material, additional treatment cost, risk of infection or disease transmission as well as they can be refused by patients for religious reasons or because they are in contrast with chosen lifestyle [11-13,17,24,25]. Moreover, non-resorbable membranes or titanium reinforced membranes needs to be removed if they are exposed during the healing phase, which significantly compromises the principles of guided bone regeneration and patient's perception of the surgical intervention [26,27].

Consequently, the use of barrier membrane coverage in conjunction with LARA prior to implant placement seems to be associated with pros and cons [4,7,11-13]. Previous systematic reviews have demonstrated that the use of barrier membrane coverage following LARA diminishes resorption of the augmented area, whereas no significant differences was reported in alveolar width gain or incorporation of the autogenous bone block graft with or without the use of barrier membrane coverage [7,17,28,29]. However, the efficiency of barrier membrane coverage on survival of implants or suprastructures as well as patient-reported outcome measures (PROM) have never previously been assessed in a systematic review.

The objective of the present systematic review is therefore to test the hypothesis of no difference in implant treatment outcome following lateral alveolar ridge augmentation with the use of an autogenous bone block graft alone with or without barrier membrane coverage.

MATERIAL AND METHODS

Protocol and registration

The present systematic review was conducted in accordance with the Preferred Reporting Items for Systematic reviews and Meta-Analyses (PRISMA) statement for reporting systematic reviews [30,31]. The methods of the analysis and inclusion criteria were specified in advance and documented in a protocol. The review was registered in PROSPERO, an international prospective register of systematic reviews.

Registration number: CRD42021237354.

The protocol can be accessed at:

https://www.crd.york.ac.uk/prospero/display_record.php?ID=CRD42021237354.

Focus question

The focus question was developed according to the Patient, Intervention, Comparison and Outcome (PICO) framework as described in Table 1.

Focus question: Are there any differences in implant treatment outcome following LARA with an autogenous bone block graft alone with or without barrier membrane coverage?

Types of studies

The present systematic review included randomised controlled trials on humans.

Table 1. PICOS guidelines

Patient and population (P)	Healthy adult patients with atrophy of the alveolar process receiving lateral alveolar ridge augmentation with an autogenous bone block graft prior to implant placement.
Intervention (I)	Barrier membrane coverage.
Comparator or control group (C)	No barrier membrane coverage.
Outcomes (O)	Primary outcome measures included survival of implants and suprastructures. Secondary outcome measures included peri-implant marginal bone loss, two-dimensional width changes, three-dimensional volumetric width changes, bone regeneration, PROM, biological and mechanical complications.
Study design (S)	Randomised controlled trials.
Focused question	Are there any differences in implant treatment outcome following lateral alveolar ridge augmentation with an autogenous bone block graft alone with or without barrier membrane coverage?

Population

Edentulous or partially edentulous healthy adult patients with horizontal atrophy of the alveolar ridge receiving LARA with an autogenous bone block graft alone with or without barrier membrane coverage prior to placement of dental implants.

Types of outcome measures

The primary outcome measures included:

- Survival of implants. Estimated by subtraction of failed implants, which was defined as mobility of previously clinically osseointegrated implants or removal of non-mobile implants due to progressive PIMBL or infection.
- Survival of suprastructures. Estimated by subtraction of failed suprastructures, which was defined as a total loss of the suprastructures due to mechanical and/or biological complications.

The following secondary outcome measures were also assessed:

- PIMBL. Evaluated by radiographic measurements.
- Two-dimensional width changes of the alveolar ridge following LARA including gain as well as subsequently resorption. Estimated by clinical and radiographic measurements.
- Three-dimensional volumetric width changes of the alveolar ridge following LARA including gain as well as subsequently resorption. Estimated by three-dimensional radiographic measurements and computer software.
- Bone regeneration. Histomorphometric analysis of new bone formation, non-mineralized tissue or remnants of the barrier membrane.
- PROM.
- Biological and mechanical complications.

Information sources

The search strategy incorporated examinations of

electronic databases, supplemented by a thorough hand-search page by page of relevant journals including “British Journal of Oral and Maxillofacial Surgery”, “Clinical Implant Dentistry and Related Research”, “Clinical Oral Implants Research”, “European Journal of Oral Implantology”, “Implant Dentistry”, “International Journal of Oral and Maxillofacial Implants”, “International Journal of Oral and Maxillofacial Surgery”, “International Journal of Periodontics and Restorative Dentistry”, “International Journal of Prosthodontics”, “Journal of Clinical Periodontology”, “Journal of Dental Research”, “Journal of Oral Implantology”, “Journal of Oral & Maxillofacial Research”, “Journal of Periodontology”, “Journal of Prosthetic Dentistry”, “Journal of Craniofacial Surgery”, “Journal of Cranio-Maxillo-Facial Surgery”, “Journal of Oral and Maxillofacial Surgery”, “Periodontology 2000”, “Oral and Maxillofacial Surgery” and “Oral Surgery Oral Medicine Oral Pathology Oral Radiology”. The manual search also included the bibliographies of all articles selected for full-text screening as well as previously published reviews relevant for the present systematic review. Two reviewers (R.G. and L.Q.) independently performed the search. In the event of disagreement, another reviewer was consulted (T.S-J.).

Search

A PubMed (MEDLINE), Embase, and Cochrane Library search was conducted. Human studies published in English until the 8th of February 2021 were included. Grey literature, unpublished literature as well as other databases like Scopus, Google Scholar, or Research Gate were not included in the search strategy of the present systematic review. The search strategy was performed in collaboration with a librarian and utilized a combination of Medical Subject Heading (MeSH) and free text terms. The search strategy is outlined in [Appendices 1, 2, 3 and 4](#).

Selection of studies

PRISMA flow diagram presents an overview of the selection process. The titles of the identified reports were initially screened, and duplicates were removed. The abstract was assessed when the title indicated that the study was relevant. Full-text analysis was obtained for those with apparent relevance or when the abstract was unavailable. The references of the identified papers and previously published systematic reviews were cross-checked for unidentified articles. Study selection was performed by two reviewers (R.G. and L.Q.). In the event of disagreement between the reviewers, another reviewer was consulted (T.S-J.). The level of agreement between the reviewers was tested using Cohen's kappa coefficient (k).

Study eligibility

The inclusion criteria were developed using the PICOS guidelines as outlined in Table 1.

Inclusion criteria

Randomised controlled trials assessing implant treatment outcome following LARA with an autogenous bone block graft alone with or without barrier membrane coverage were included by addressing the previously described outcome measures. The review exclusively focused on studies using autogenous bone block graft with lag-screw fixation prior to delayed implant placement. In addition, at least 10 patients should be included with an observation period longer than three months. Moreover, number of surgical procedures, type of barrier membrane and selection of donor site should be clearly specified.

Exclusion criteria

Following exclusion criteria were applied: implant placement in medically compromised patients, simultaneous implant placement as well as insufficient description of the performed numbers of surgical procedures or length of observation period were excluded. Moreover, letters, editorials, PhD theses, letters to the editor, case reports, abstracts, technical reports, conference proceedings, animal or *in vitro* studies and literature review papers were also excluded.

Data extraction

Data were extracted by one reviewer (R.G.)

according to a data-collection form ensuring systematic recording of the outcome measures. In addition, relevant characteristics of the study were recorded. The corresponding author was contacted by e-mail in the absence of important information or uncertainties.

Data items

The following items were collected from the included studies and arranged in the following fields: author, year of publication, study design, patients, LARA, donor site, membrane, number of inserted implants, length of observation period, survival of implants and suprastructures, PIMBL, two-dimensional and three-dimensional changes of the augmented area, histomorphometric analysis, PROM as well as biological and mechanical complications.

Assessment of methodological quality

The quality assessment of the included studies was undertaken by one reviewer (R.G.) as part of the data extraction process. Risk of bias assessment was performed according to the Cochrane Handbook for Systematic Reviews of Interventions [32]. The included studies were categorised as; "low risk" (plausible bias unlikely to seriously alter the results), "unclear risk" (plausible bias that raises some doubt about the results) or "high risk" (plausible bias that seriously weakens confidence in the results).

The overall risk of bias was assessed, and included studies were categorized according to:

- Low risk of bias (low risk of bias in all key domains);
- Unclear risk of bias (unclear risk of bias in one or more key domains);
- High risk of bias (high risk of bias in one or more key domains).

Statistical analysis

Data management and statistical analysis was performed using Microsoft Office Excel version 2013 (Microsoft Corporation; Washington, USA) and statistical software STATA release 17 (StataCorp LLC; Missouri, USA). Meta-analyses including 95% confidence interval (CI) were performed, if there were studies of similar comparison, reporting identical outcome measures. Parametric data were expressed in the text and tables as mean or median, standard deviation (M [SD]) or range. Mean and standard deviation were calculated from reported data or calculated from median, minimum and maximum.

Random-effects meta-analyses were performed using the Sidik-Jonkman estimation method. Forestplots and funnelplots were made in software STATA. Statistical significance level was defined at $P = 0.05$.

Assessment of heterogeneity

The significance of any discrepancies in the estimates of the treatment effects of the different studies was assessed by means of Cochran’s test for heterogeneity and the I^2 statistic, which describes the percentage of total variation across studies that is due to heterogeneity rather than chance. Heterogeneity by Cochran’s test was considered statistically significant if $P < 0.1$. A rough guide to the interpretation of I^2 given in the Cochrane Handbook for Systematic Reviews of Interventions. Reviews of interventions is as follows [32]:

- 0 to 40% the heterogeneity might not be important;
- 30 to 60% may represent moderate heterogeneity;
- 50 to 90% may represent substantial heterogeneity;
- 75 to 100% may represent considerable heterogeneity.

RESULTS

Study selection

Articles review and data extraction were performed according to the PRISMA flow diagram (Figure 1). The electronic search resulted in 410 entries. One article was identified through hand-searching. Of these 411 articles, 177 were excluded because they had been retrieved in more than one search. A total of 29 abstracts were reviewed and full-text analysis included 10 articles. Finally, five studies were included in the present systematic review [18,33-36]. The level of agreement between the two authors (R.G. and L.Q.) in selecting studies to be read in full text was measured at $k = 0.82$, while level of agreement between the two authors (R.G. and L.Q.) for eligibility assessment was measured at $k = 1$.

Exclusion of studies

Reasons for excluding studies after full-text assessment were as follows: the study design was not considered as a randomised controlled trial [13], identical patient sample and reported outcome were presented with a longer observation period in one of

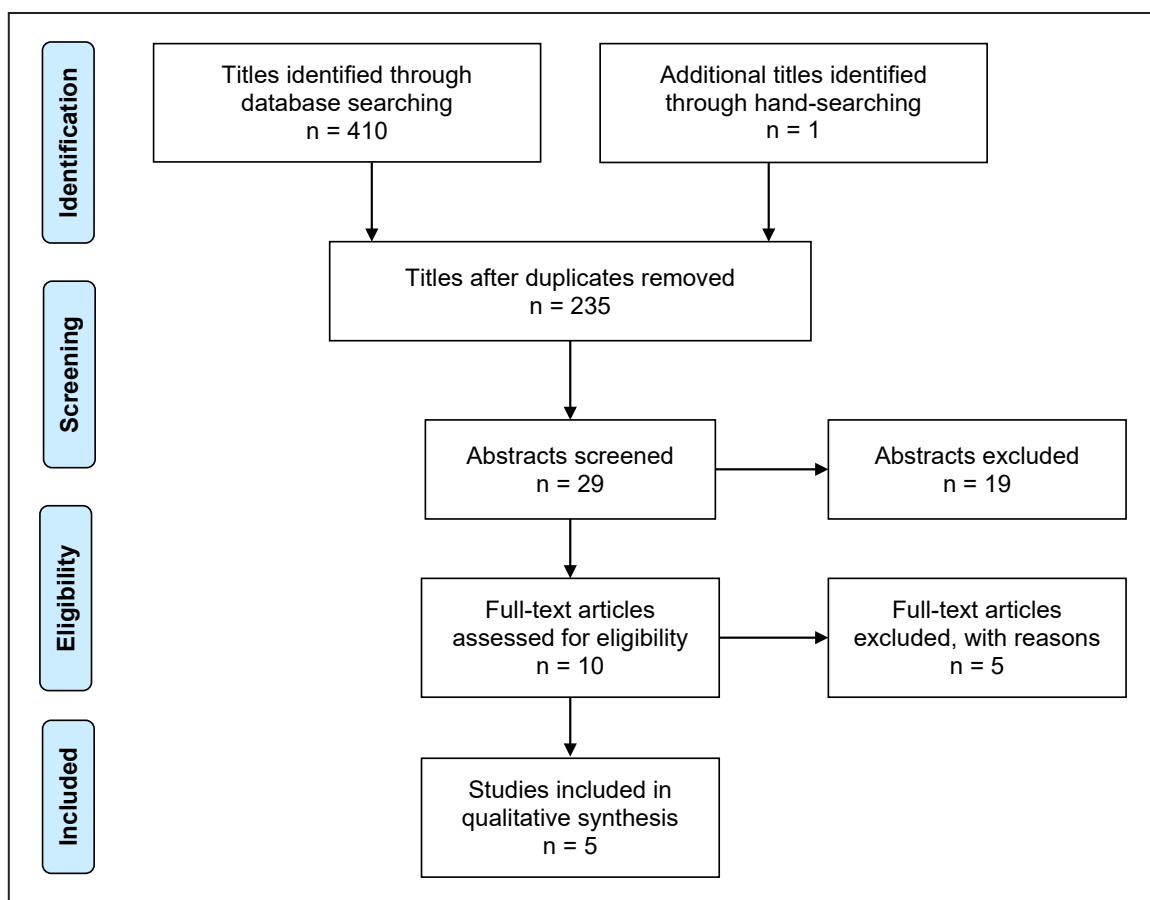


Figure 1. PRISMA flow diagram demonstrating the results of the systematic literature search.

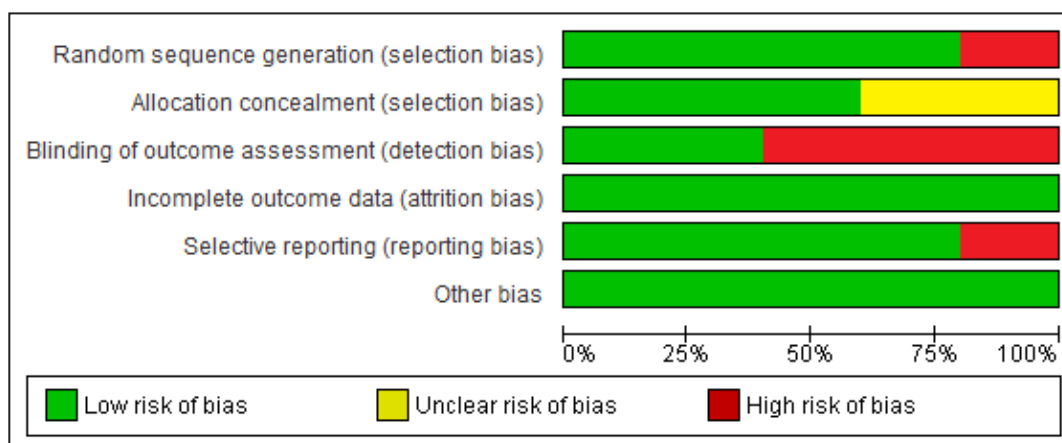


Figure 2. Risk of bias graph.

the included studies [37], osteoporotic patients were included [38], simulations implant placement in conjunction with LARA [39], and an autogenous bone block graft was not used as grafting material [40].

Quality assessment

The quality of the included studies is summarized in Figures 2 and 3. Three studies were characterised by low risk of bias [18,35,36], and two studies with high risk of bias [33,34].

Study characteristics

The included studies of the present systematic review consisted of five randomised controlled trials [18,33-36]. A parallel arm design was used in four studies [18,34-36], whereas a split-mouth study design was used in one study [33]. No significant difference in patient demographics were reported in two studies [34,36]. Inclusion and exclusion criteria were clearly specified in four studies [18,34-36], whereas one study solely reported inclusion criteria [33]. Power calculation was not performed in any of the included studies. Randomisation was conducted using a computer generated random allocation process [33,35,36], using draw of lots [18] or no information was provided about the randomisation procedure [34]. The autogenous bone block graft was harvested from the mandibular symphysis [18,35,36], iliac crest [33], or maxilla palate [34]. Different barrier membranes were used involving a non-resorbable expanded-polytetrafluoroethylene (e-PTFE) membrane (W.L. Gore & Associates; Flagstaff, Arizona, USA) [18], resorbable collagen membrane (Bio-Gide® - Geistlich Pharma AG; Wolhusen, Switzerland) [33,35,36], or a unspecified platelet rich fibrin (PRF) membrane [34]. The surgical procedures were performed by one surgeon [33-35] or no information was provided




Figure 3. Risk of bias summary.

about the number of surgeons involved in the study [18,36]. LARA was performed under local anaesthesia in four studies [18,34-36] or general anaesthesia in one study [33]. The autogenous bone block graft was fixated with one or two osteosynthesis screws in all the included studies [18,33-36]. Delayed implant placement was performed after three to six months in four studies [18,33,35,36], while timing of implant placement was not reported in one study [34]. Different implant systems were used including screw-type machined-surface implants (Brånemark System®; Nobel Biocare, Gothenburg,

Sweden) [18], abrasive-blasted, acid-etched, rough surface screw-type implants (Camlog RootLine implants, Camlog Biotechnologies, Wimsheim, Germany) [33], solid sandblasted, large-grit, acid-etched, rough surface screw-type implants (ITI Implant System - Institute Straumann; Waldenberg, Switzerland) [33] and solid sand-blasted, large-grit, acid-etched, rough surface screw-type implants (Straumann Plus implants, Institute Straumann, Waldenberg, Switzerland) [35,36]. The final prosthetic rehabilitation included fixed prostheses in two studies [35,36], whereas no information was provided about the prosthetic solution in three studies [18,33,34]. Two-dimensional linear measurements of the alveolar ridge was performed using intraoperative caliper measurement with an individual stent as well as standardized CT-scans with an electronic caliper involving two separated measurements [18], intraoperative caliper measurements at the implant position involving a single measurement [35], intraoperative digital caliper measurements adjacent to the fixation screw involving a single measurement [33], or intraoperative manual caliper involving three measurements [34]. Volumetric assessment of the augmented area involving three-dimensional measurements with the use of computer software was not performed in any of the included studies. Biopsies for histomorphometric assessment of the total bone volume, newly formed bone and non-mineralized tissue were obtained with a trephine bur at the planned implant position, three months after LARA [33,35]. PROM was assessed by self-administrated questionnaire [36]. Assessment of patient satisfaction and the aesthetic result was performed by the same trained prosthodontist, who was unaware of the applied method [36]. Information about training or calibration of the examiners assessing the clinical outcome was described in one study [36]. Numbers of dropouts were reported in all included studies [18, 33-36].

Outcome measures

The result of each outcome measure is presented first and then a short summary is provided. Outcome measures are outlined in Table 2, apart from PROM as well as biological and mechanical complications, which are solely described in the following section. Three-dimensional volumetric width changes of the augmented area following LARA with or without barrier membrane coverage was not assessed in any of the included studies. Thus, this outcome measure is not reported in the following section or in Table 2.

Primary outcome measures

Survival of implants

Survival of implants was reported in four of the included studies [18,33,35,36].

The 10-year implant survival rate was 93.5% following LARA with a Bio-Gide® membrane compared with 100%, when no barrier membrane coverage was used [36]. There was no significant difference in implant survival rate between the two treatment modalities ($P = 0.156$) [36]. Two implants were removed due to soft tissue recession or buccal bone resorption, after two and six years, respectively [36]. The three-months implant survival rate was 100% following LARA with or without a Bio-Gide® membrane [33]. The implant survival rate was 100% following LARA with or without a Bio-Gide® membrane, after 20 months [35]. The six-months implant survival rate was 100% following LARA with or without an e-PTFE membrane [18].

Summary

LARA with or without barrier membrane coverage seems to be associated with high implant survival rate. However, a non-significant higher implant survival rate was reported in a long-term study when no membrane coverage was used. Consequently, further long-term studies are needed before conclusions can be provided about the implant survival rate following LARA with or without barrier membrane coverage.

Survival of suprastructures

Survival of suprastructures were reported in two of the included studies [35,36].

The 10-year survival rate of suprastructure was 87.1% following LARA with or without a Bio-Gide® membrane [36]. No significant difference was reported between the two treatment modalities ($P = 1.00$). A total of 11 suprastructures were considered failures due to porcelain chipping or loss of implant [36].

The 1-year survival rate of the suprastructure was 100% following LARA with or without a Bio-Gide® membrane [35].

Summary

LARA with or without barrier membrane coverage seems to be associated with high survival rates of suprastructures.

Table 2. Lateral alveolar ridge augmentation with autogenous bone block graft with or without barrier membrane coverage

Author	Year of publication	Study design	PT	Materials and methods					Outcome measures						
				LARA	Donor site	Membrane	NOI	LOP (months)	IS (%)	SS (%)	PIMBL	Two-dimensional		Histomorphometric	
												Mean (SD)/range (mm)		Mean (SD)/range (mm)	
												GARW	RAA	TBV/NB	NMB
Antoun et al. [18]	2001	Parallel	12	13	Mandibular symphysis	e-PTFE: 5 None: 8	5 8	6	100	NR	NR	3.7 (SD 1.8) 2.9 (SD 1.4)	0.3 (SD 0.4) ^a 2.3 (SD 1)	NR	
Heberer et al. [33]	2009	Split-mouth	14	33	Iliac crest	Bio-Gide®: 17 None: 16	92	3	100	NR	NR	NR	1 (range 0.3 to 3.4) ^b 1 (range 0.4 to 2.1)	3 months 48 (range 5 to 94) 29 (range 1 to 52) 43 (range 3 to 98) ^c 26 (range 2 to 63)	
Moussa et al. [34]	2016	Parallel	12	13	Maxilla palate	PRF: 7 None: 6	NR	4	NR	NR	NR	2.7 (SD 0.7) ^d 2.1 (SD 0.8)	0.8 (SD 0.6) ^e 1.7 (SD 0.8)	NR	
Meijndert et al. [35]	2005	Parallel	10	10	Mandibular symphysis	Bio-Gide®: 5 None: 5	10	20	100	100	NR	3.4 (SD 1.1) 3 (SD 1)	NR	3 months 57.2 (SD 11.5) 42.3 (SD 11.5) 55.2 (SD 6.8) 44.8 (SD 6.8)	
Meijndert et al. [36]	2017	Parallel	62	62	Mandibular symphysis	Bio-Gide®: 31 None: 31	62	120	93.5 100	87.9	0.5 (SD 1.2)	NR	NR	NR	

^a(P = 0.001), ^b(P = 0.38), ^c(P = 0.46), ^d(P = 0.138), ^e(P = 0.006).

e-PTFE = expanded polytetrafluoroethylene; GARW = gain alveolar ridge width; IS = implant survival; LARA = lateral alveolar ridge augmentation; LOP = length of observation period; NB = new bone; NMB = new mineralized bone; NOI = number of implants; NR = not reported; PRF = platelet rich fibrin; PT = number of patients at baseline; RAA = resorption augmented area; SD = standard deviation; SS = suprastructure survival; TBV = total bone volume.

Secondary outcome measures

Peri-implant marginal bone loss

PIMBL was reported in one of the included studies [36].

The 10-year PIMBL was 0.48 mm and 0.3 mm at the mesial and distal side of the implant following LARA with or without a Bio-Gide® membrane, respectively. There was no significant difference in PIMBL between the two treatment modalities ($P = 0.19$ and $P = 0.92$) [36].

Summary

LARA with or without barrier membrane coverage seems to be associated with limited long-term PIMBL.

Two-dimensional width changes of the alveolar ridge

Two-dimensional width change of the alveolar ridge was reported in four of the included studies [18, 33-35].

Gain in alveolar ridge width following LARA with an e-PTFE membrane was 3.7 mm compared with 2.9 mm, when no barrier membrane was used, six months after LARA [18]. No significant difference between the two treatment modalities was reported, though no statistically analysis was conducted [18]. The estimated resorption of the alveolar ridge was 0.3 mm with the use of an e-PTFE membrane compared with 2.3 mm, when no barrier membrane coverage was used [18]. The difference was statistically significant ($P < 0.01$) [18].

Gain in alveolar ridge width following LARA with a Bio-Gide® membrane was 3.4 mm compared with 3 mm, when no barrier membrane was used, three months after LARA [35]. No statistically analysis was conducted [35].

Gain in alveolar ridge width following LARA with a PRF membrane was 2.7 mm compared with 2.2 mm, when no barrier membrane was used, four months after LARA [34]. There was no significant difference between the two treatment modalities ($P = 0.138$). The estimated resorption of the alveolar ridge was 0.8 mm with a PRF membrane compared with 1.6 mm, when no barrier membrane was used [34]. The difference was statistically significant ($P < 0.006$) [34].

The median resorption of the alveolar ridge following LARA with a Bio-Gide® membrane was 1 mm (range 0.3 to 3.4) compared with 1 mm (range 0.4 to 2.1), when no barrier membrane was used, three months after LARA [33]. There was no significant difference between the two treatment modalities ($P = 0.38$).

Summary

The gain in alveolar ridge width following LARA seems to be unaffected by the use of a barrier membrane, while barrier membrane coverage seems to be associated with diminished resorption of the augmented area compared with no barrier membrane coverage. However, the results of the included studies are based on short-term observation periods using two-dimensional linear assessment methods.

Bone regeneration

Histomorphometric analysis of bone regeneration was reported in two of included studies [33,35].

Percentages of total bone volume, new bone formation and non-mineralized tissue following LARA with a Bio-Gide® membrane was 71%, 48%, and 23% compared with 74%, 43%, and 26%, when no barrier membrane was used, three months after LARA [33]. No statistically analysis was applied [33].

Percentages of total bone volume and non-mineralized tissue following LARA with a Bio-Gide® membrane was 57.7% and 42.3% compared with 55.2% and 44.8%, when no barrier membrane was used, three months after LARA [35]. There was no significant difference between the two treatment modalities ($P = 0.46$) [35].

Summary

LARA with or without barrier membrane coverage seems to be associated with comparable histomorphometric outcomes. However, these results are based on two short-term studies.

PROM

PROM was reported in one of the included studies [36].

The 10-year overall patient satisfaction with the treatment outcome was 98.6% and the overall satisfaction score was 8.6 (highest value was 10) as evaluated by Implant Crown Aesthetic Index (ICAI) following LARA with or without a Bio-Gide® membrane [36]. There was no significant difference between the two treatment modalities ($P = 0.99$). Patients were least happy with the mucosal appearance and only 59.7% of the patients were completely satisfied with the surrounding mucosa after ten years [36].

Summary

LARA with or without barrier membrane coverage

seems to be associated with high long-term patient satisfaction. However, appearance of the surrounding mucosal gave rise to less patient satisfaction.

Biological and mechanical complications

Biological and mechanical complications were reported in four of the included studies [18,33,34,36]. Mucosal dehiscence seems to be the most frequent complications following LARA with or without barrier membrane coverage [18,33,34,36]. There was no significant difference in mucosal dehiscence between the two treatment modalities [18,33,34,36]. Infection, epistaxis and loss of the autogenous bone block graft following LARA with or without barrier membrane coverage were reported infrequently [18,34]. Mechanical complications including porcelain crown fracture were reported in one study describing no significant difference between the two treatment modalities, although a statistically analysis was not applied [36].

Summary

The frequency and severity of biologic and mechanical complications following LARA with or without barrier membrane coverage seems to be comparable.

Mucosal dehiscence appears to be the most common complication with the two treatment modalities.

Meta-analysis

Meta-analyses were to be conducted only if there were studies of similar comparison, reporting identical outcome measures. However, the included studies of the meta-analysis revealed substantial variations in study design, i.e., initial width of the alveolar ridge, type of barrier membrane, assessment methods and length of observation period. Consequently, a well-defined meta-analysis was not applicable. Instead, a meta-analysis (with random effect) where conducted using Sidik-Jonkman estimation method for assessment of dimensional width changes of the alveolar ridge across comparable studies including forest plots. Mean and SD were calculated from reported data or calculated from median, minimum and maximum using previous described methods [41]. A non-significant gain in alveolar ridge width of 0.5 mm (CI = -0.1 to 1.1) and diminished postoperative alveolar ridge resorption of -0.9 mm (CI = -2.4 to 0.7) were revealed following LARA with the use of barrier membrane coverage compared with no barrier membrane coverage (Figure 4 and 5).

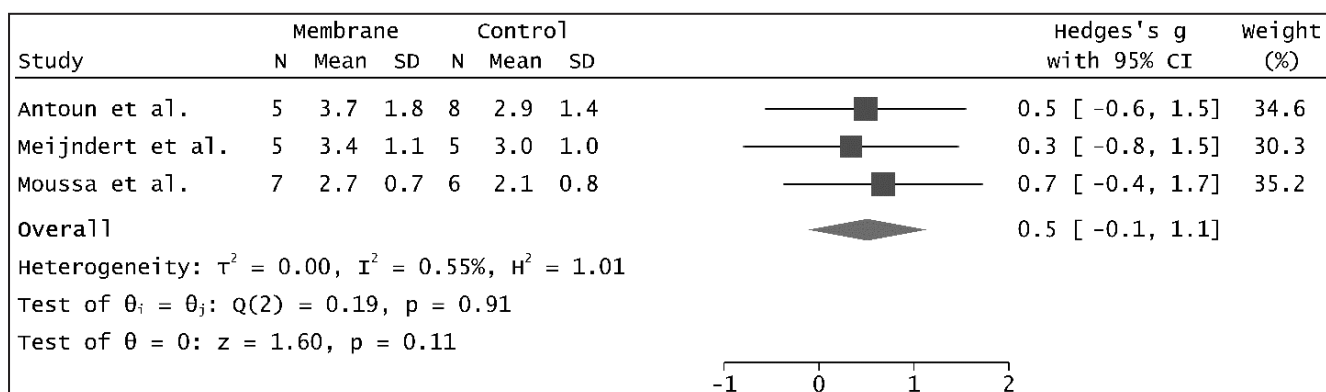


Figure 4. Random-effects meta-analysis using Sidik-Jonkman estimation method revealing no statistically significant differences in gain alveolar ridge width changes with the use of barrier membrane coverage compared with no barrier membrane coverage.

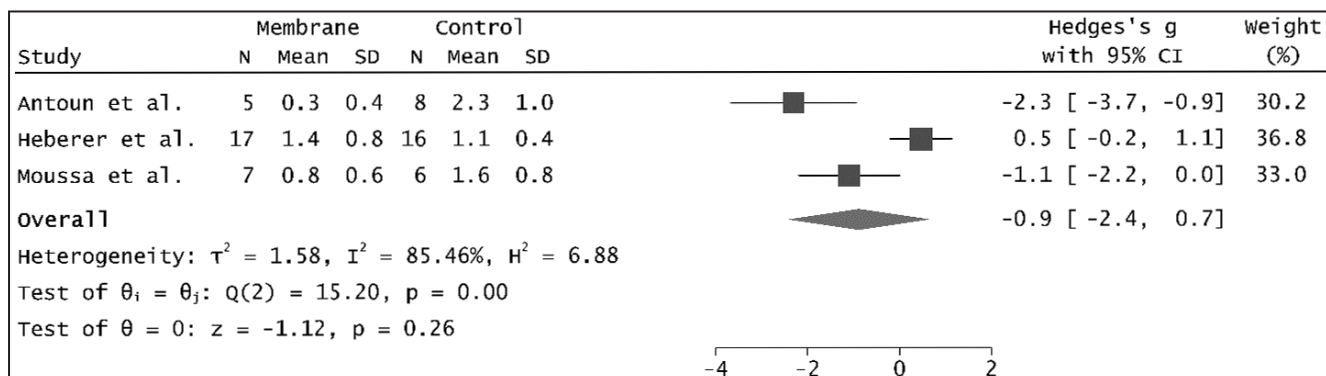


Figure 5. Random-effects meta-analysis using Sidik-Jonkman estimation method revealing no statistically significant differences in resorption augmented area changes with the use of barrier membrane coverage compared with no barrier membrane coverage.

A non-significant difference in heterogeneity was revealed between studies assessing gain in alveolar ridge ($I^2 = 0.55\%$, $P = 0.91$), whereas studies assessing postoperative alveolar ridge resorption revealed a significantly difference in heterogeneity ($I^2 = 85.46\%$, $P = 0.00$). Funnel plots of the included studies are presented in Figure 6 and 7. Larger studies with higher power are placed towards the top (smaller standard errors), while lower powered studies are placed towards the bottom. Eggers test did not indicate small-study effects for studies assessing gain in alveolar ridge width ($P = 0.7$), while small-study effects were indicated for studies assessing postoperative alveolar ridge resorption ($P = 0.00$).

DISCUSSION

The objective of this systematic review was to test the hypothesis of no difference in implant treatment outcome following LARA with an autogenous bone block graft alone with or without barrier membrane coverage. Three randomised controlled trials characterised by low risk of bias [18,35,36], and two with high risk of bias [33,34] fulfilled the inclusion criteria and were included in the present systematic review. Comparable implant treatment outcome was revealed with the two treatment modalities. Meta-analysis disclosed a non-significant gain in alveolar ridge width of 0.5 mm (CI = -0.1 to 1.1)

and diminished postoperative alveolar ridge resorption of -0.9 mm (CI = -2.4 to 0.7) following LARA with the use of barrier membrane coverage compared with no barrier membrane coverage. Consequently, LARA with the use of barrier membrane coverage seems to have a beneficial effect on alveolar ridge gain and postoperative dimensional changes of the augmented area. However, substantial variations in study design, patient sample, observation periods and type of assessment methods as well as various methodological confounding factors posed significant limitations to review the literature in a quantitative systematic manner.

LARA with the use of an autogenous bone block graft in conjunction with barrier membrane coverage is the most commonly used surgical procedure to enhance the severely atrophic alveolar ridge. However, well-defined implications and benefits for using resorbable or non-resorbable barrier membranes in conjunction with LARA have never previously been determined. The various types of xenogeneic or synthetic barrier membrane contain dissimilar material properties which are intended to improve bone regeneration and hamper soft tissue interference [22,23]. Moreover, a recent review evaluated the efficacy of guided bone regeneration membranes as bioactive compartment in addition to the established function as a barrier. The authors concluded that barrier membranes have an important bioactivity role in hosting and modulating the molecular activities of the cells during guided bone regeneration [42].

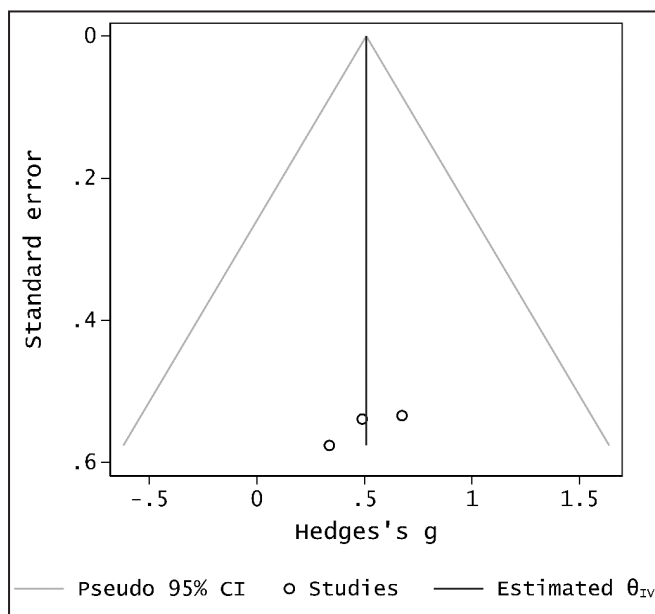


Figure 6. Funnel plot to visualized heterogenicity among the included studies for assessment of differences in gain alveolar ridge width changes. Larger studies with higher power are placed towards the top (smaller standard errors) and lower powered studies towards the bottom. An asymmetry in the funnel plot indicate bias. Eggers test did not indicate small-study effects (P-value = 0.7).

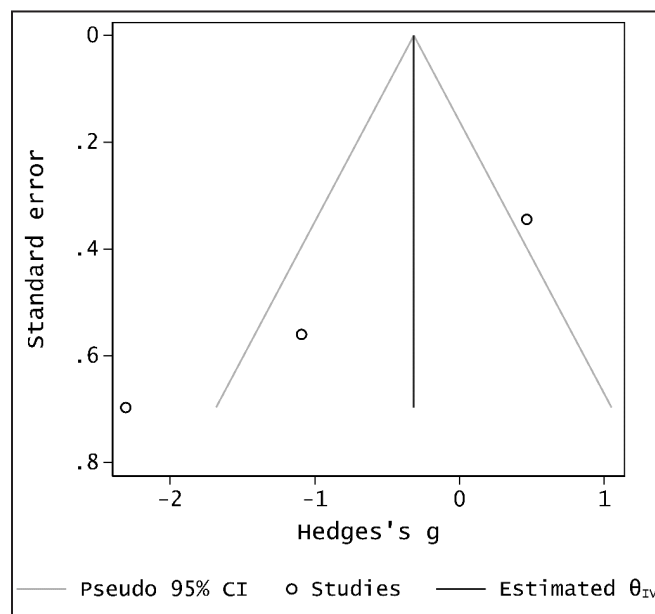


Figure 7. Funnel plot to visualized heterogenicity among the included studies for assessment of differences in resorption augmented area changes. Larger studies with higher power are placed towards the top (smaller standard errors) and lower powered studies towards the bottom. An asymmetry in the funnel plot indicate bias. Eggers test did not indicate small-study effects (P-value = 0.00).

However, barrier membrane coverage in conjunction with LARA is associated with increased risk of infection, religious issues and additional treatment cost, which influence the treatment decision-making process.

From a clinical and patient perspective, survival of implants and suprastructures are generally accepted as the most important outcome measures for assessing long-term results of implant treatment outcome. The included studies of the present systematic review demonstrated high survival rates of implants and suprastructures following LARA with or without barrier membrane coverage [18,33-36], although long-term results were only reported in one of the included studies [36]. Consequently, the use of barrier membrane coverage seems not to influence survival rates of implants and suprastructures following LARA with an autogenous bone block graft, although further long-term randomised controlled trials are needed to substantiate this conclusion.

Secondary outcome measures were included in the present systematic review since barrier membrane coverage in conjunction with LARA is attended to maintain the augmented area and diminish postoperative dimensional changes of the alveolar ridge, which have significant implications for the primary outcome measures as well as patients' perspective of the surgical intervention and the final prosthodontic solution. A criterion of successful implant treatment is PIMBL of less than 1 to 1.5 mm during the first year after implant loading and less than 0.2 mm annually, which in turn corresponds to 3.3 mm after 10 years [43]. The 10-year PIMBL following LARA with an autogenous bone block graft with or without barrier membrane coverage was less than 0.5 mm [36], which is in accordance with the success criterion [36]. However, further long-term studies assessing PIMBL following LARA with or without barrier membrane coverage are needed before definitive conclusions can be provided.

LARA with an autogenous bone block graft alone with or without barrier membrane coverage is characterised by an inhomogeneous and three-dimensional anisotropic structure, which is why three-dimensional methods should be applied for assessment of dimensional width changes of the augmented area. However, two-dimensional linear clinical or radiographic measurements were used in all the included studies of the present systematic review revealing a non-significant tendency to increased gain in alveolar ridge width and diminish postoperative resorption with the use of barrier membrane coverage [18,33-35]. High degree of reliability, accuracy and reproducibility in quantifying volumetric changes

of the augmented area following LARA with the use of three-dimensional computer software have previously been reported in clinical and experimental studies [44,45]. A previous study using three-dimensional volumetric assessment of the augmented area following LARA with an autogenous bone block graft alone from the iliac crest without barrier membrane coverage revealed a volume reduction of the augmented area by 78%, whereas two-dimensional linear measurements disclosed an alveolar ridge reduction from 11,2 mm to 5,6 mm corresponding to 50%, after two years [46]. Consequently, three-dimensional volumetric assessment of dimensional alveolar ridge changes following LARA should be included in future randomised controlled trials, since two-dimensional measurements seems to underestimate the accurate dimensional changes of the augmented area.

The microarchitecture of the autogenous bone block graft varies among the included studies [25,47]. Monocortical bone blocks harvested from the mandible or primarily cortico-cancellous bone blocks from the iliac crest has different microarchitecture, revascularisation patterns and embryonic origin [25,47,48]. Previous studies have demonstrated that intramembranous bone blocks harvested from the maxillae or mandible disclosed a lower resorption rate compared with endochondral bone blocks from the iliac crest [48,49]. However, recent findings have attributed the slower resorption due to microarchitecture of the bone. Especially the ratio between cortical and cancellous bone has a significant impact on the resorption of the bone [48].

Resorbable or non-resorbable membranes in conjunction with LARA acts as a mechanical barrier to exclude soft-tissue ingrowth and improve bone regeneration [22,23]. The included studies of the present systematic review revealed comparable total bone volume, new bone formation and non-mineralized tissue following LARA with autogenous bone block graft with or without barrier membrane coverage, after three months [33,35]. Previous studies assessing histomorphometric outcome following LARA with autogenous bone block graft from the ascending mandibular ramus or chin with or without barrier membrane coverage have demonstrated substantial amounts of non-vital bone, empty osteocyte lacunae and generally weak neo-vascularization, after three to nine months [50-52]. These studies indicate that LARA with an autogenous bone block graft with or without barrier membrane coverage is associated with significant amount of non-vital bone at the time of implant placement, which is inconsistent with the results of the present systematic review [33,35].

Consequently, further randomised controlled trials assessing the histomorphometric outcome following LARA with or without barrier membrane coverage is needed before the beneficial effect of barrier membrane coverage on bone regeneration in conjunction with LARA can be established.

Survival of implants and suprastructures were designated as the primary outcome measures of the present systematic review, since these parameters are commonly used to define a successful implant treatment outcome [11,53]. However, clinical parameters do not necessarily reflect patient's expectations and satisfaction with the surgical intervention or the final implant-supported restoration. Assessment of a successful implant treatment outcome should therefore also include patient-related issues and not only focus on objective criteria. PROM following LARA with an autogenous bone block graft with or with barrier membrane coverage has solely been assessed in one long-term study disclosing high patient satisfaction, although the appearance of the surrounding mucosal gave rise to less patient satisfaction [36]. Aesthetic aspects of the implant restorations and surrounding mucosa as well as phonetics and chewing comfort are important criteria for a successful implant treatment [54]. However, previous studies have demonstrated that the cost of an implant treatment also affects the level of patient satisfaction [55,56]. The use of barrier membrane coverage in conjunction with LARA increases the total cost of an implant treatment, which potentially could influence patient satisfaction with the final implant treatment outcome and decision-making process. Consequently, financial cost and PROM should be included in further randomised studies assessing LARA with or without the use of barrier membrane coverage.

The degree of patient satisfaction is also influenced by the frequency and severity of complications. Biologic and mechanical complications following LARA with or without barrier membrane coverage seems to be diminutive [54]. Mucosal dehiscence appears to be the most common complication with the two treatment modalities, which is in accordance with previous published systematic reviews [7,17,28,29]. Mucosal dehiscence and barrier membrane exposure is often associated with less bone regeneration and resorption of the augmented area, which may compromise implant placement in an optimal prosthetically position [57]. However, mucosal dehiscence with exposed barrier membrane is usually treated sufficiently with either daily application of antiseptics, use of systemic antimicrobials or removal of the sequestered bone [57]. The need for total removal

of a non-integrated autogenous bone block graft in conjunction with a mucosal dehiscence rarely occurs, but additional alveolar ridge augmentation at the time of implant placement is often necessitated in the case of a mucosal dehiscence [3,28].

Systematic reviews provide a meticulous summary of the current knowledge related to a defined research question and meta-analysis is the statistical method that integrate the results from the included studies. The strength of evidence from a systematic review and meta-analysis is therefore related to the scientific quality of the included studies and independence of various biases. High quality randomised controlled trials with low risk of bias provide the highest level of evidence for ascertaining the safety and efficacy of a specific surgical intervention. The conclusion of the present systematic review and meta-analysis is based on three randomised controlled trials characterised by low risk of bias [18,35,36], and two with high risk of bias [33,34]. Consequently, the current level of evidence concerning LARA with an autogenous bone block graft alone with or without barrier membrane coverage seems to be inadequate to propose implications for evidence based clinical guidelines according to the focus question of the present systematic review.

CONCLUSIONS

The present systematic review and meta-analysis revealed no statistically significant difference in implant treatment outcome following lateral alveolar ridge augmentation with an autogenous bone block graft alone with or without barrier membrane coverage. Comparable implant treatment outcome was revealed with the two treatment modalities, though a non-significantly beneficial effect in gain of alveolar ridge width and diminished postoperative dimensional changes of the augmented area was disclosed with the use of barrier membrane coverage. However, substantial variations in study design, patient sample, observation periods and type of assessment methods as well as various methodological confounding factors posed significant limitations to review the literature in a quantitative systematic manner. The conclusions of the current systematic review should therefore be interpreted with caution and well-designed long-term randomised controlled trials following the Consolidated Standards of Reporting Trials guidelines are required before definitive conclusions can be provided about the efficacy of barrier membrane coverage following lateral alveolar ridge augmentation with an autogenous bone block graft alone.

ACKNOWLEDGMENTS AND DISCLOSURE STATEMENTS

The authors report no financial or other conflicts of interest related to this publication. There were no sources of funding for this systematic review.

REFERENCES

1. Van der Weijden F, Dell'Acqua F, Slot DE. Alveolar bone dimensional changes of post-extraction sockets in humans: a systematic review. *J Clin Periodontol.* 2009 Dec;36(12):1048-58. [Medline: [19929956](#)] [doi: [10.1111/j.1600-051X.2009.01482.x](#)]
2. Tan WL, Wong TL, Wong MC, Lang NP. A systematic review of post-extractional alveolar hard and soft tissue dimensional changes in humans. *Clin Oral Implants Res.* 2012 Feb;23 Suppl 5:1-21. [Medline: [22211303](#)] [doi: [10.1111/j.1600-0501.2011.02375.x](#)]
3. Naenni N, Lim HC, Papageorgiou SN, Hämmerle CHF. Efficacy of lateral bone augmentation prior to implant placement: A systematic review and meta-analysis. *J Clin Periodontol.* 2019 Jun;46 Suppl 21:287-306. [Medline: [30624791](#)] [doi: [10.1111/jcpe.13052](#)]
4. Troeltzsch M, Troeltzsch M, Kauffmann P, Gruber R, Brockmeyer P, Moser N, Rau A, Schliephake H. Clinical efficacy of grafting materials in alveolar ridge augmentation: A systematic review. *J Craniomaxillofac Surg.* 2016 Oct;44(10):1618-1629. [Medline: [27622971](#)] [doi: [10.1016/j.jcms.2016.07.028](#)]
5. De Risi V, Clementini M, Vittorini G, Mannocci A, De Sanctis M. Alveolar ridge preservation techniques: a systematic review and meta-analysis of histological and histomorphometrical data. *Clin Oral Implants Res.* 2015 Jan;26(1):50-68. [Medline: [27007188](#)] [doi: [10.1111/clr.12288](#)]
6. Jensen AT, Jensen SS, Worsaae N. Complications related to bone augmentation procedures of localized defects in the alveolar ridge. A retrospective clinical study. *Oral Maxillofac Surg.* 2016 Jun;20(2):115-22. [Medline: [26932593](#)] [doi: [10.1007/s10006-016-0551-8](#)]
7. Sanz-Sánchez I, Ortiz-Vigón A, Sanz-Martín I, Figuero E, Sanz M. Effectiveness of Lateral Bone Augmentation on the Alveolar Crest Dimension: A Systematic Review and Meta-analysis. *J Dent Res.* 2015 Sep;94(9 Suppl):128S-42S. [Medline: [26215467](#)] [doi: [10.1177/0022034515594780](#)]
8. Gulinelli JL, Dutra RA, Maranhão HF, Simeão SFP, Groli Klein GB, Santos PL. Maxilla reconstruction with autogenous bone block grafts: computed tomography evaluation and implant survival in a 5-year retrospective study. *Int J Oral Maxillofac Surg.* 2017 Aug;46(8):1045-1051. [Medline: [28412181](#)] [doi: [10.1016/j.ijom.2017.03.019](#)]
9. Chappuis V, Cavusoglu Y, Buser D, von Arx T. Lateral Ridge Augmentation Using Autogenous Block Grafts and Guided Bone Regeneration: A 10-Year Prospective Case Series Study. *Clin Implant Dent Relat Res.* 2017 Feb;19(1):85-96. [Medline: [27476677](#)] [doi: [10.1111/cid.12438](#)]
10. Sakkas A, Wilde F, Heufelder M, Winter K, Schramm A. Autogenous bone grafts in oral implantology-is it still a “gold standard”? A consecutive review of 279 patients with 456 clinical procedures. *Int J Implant Dent.* 2017 Dec;3(1):23. [Medline: [28573552](#)] [PMC free article: [5453915](#)] [doi: [10.1186/s40729-017-0084-4](#)]
11. Aludden HC, Mordenfeld A, Hallman M, Dahlin C, Jensen T. Lateral ridge augmentation with Bio-Oss alone or Bio-Oss mixed with particulate autogenous bone graft: a systematic review. *Int J Oral Maxillofac Surg.* 2017 Aug;46(8):1030-1038. [Medline: [28366452](#)] [doi: [10.1016/j.ijom.2017.03.008](#)]
12. von Arx T, Buser D. Horizontal ridge augmentation using autogenous block grafts and the guided bone regeneration technique with collagen membranes: a clinical study with 42 patients. *Clin Oral Implants Res.* 2006 Aug;17(4):359-66. [Medline: [16907765](#)] [doi: [10.1111/j.1600-0501.2005.01234.x](#)]
13. Chiapasco M, Abati S, Romeo E, Vogel G. Clinical outcome of autogenous bone blocks or guided bone regeneration with e-PTFE membranes for the reconstruction of narrow edentulous ridges. *Clin Oral Implants Res.* 1999 Aug;10(4):278-88. [Medline: [10551070](#)] [doi: [10.1034/j.1600-0501.1999.100404.x](#)]
14. Nkenke E, Neukam FW. Autogenous bone harvesting and grafting in advanced jaw resorption: morbidity, resorption and implant survival. *Eur J Oral Implantol.* 2014 Summer;7 Suppl 2:S203-17. [Medline: [24977256](#)]
15. Starch-Jensen T, Deluiz D, Tinoco EMB. Horizontal Alveolar Ridge Augmentation with Allogeneic Bone Block Graft Compared with Autogenous Bone Block Graft: a Systematic Review. *J Oral Maxillofac Res.* 2020 Mar 31;11(1):e1. [Medline: [32377325](#)] [PMC free article: [7191383](#)] [doi: [10.5037/jomr.2020.11101](#)]
16. Cordaro L, Torsello F, Morcavallo S, di Torresanto VM. Effect of bovine bone and collagen membranes on healing of mandibular bone blocks: a prospective randomized controlled study. *Clin Oral Implants Res.* 2011 Oct;22(10):1145-1150. [Medline: [21309858](#)] [doi: [10.1111/j.1600-0501.2010.02093.x](#)]

17. Zaki J, Alnawawy M, Yussif N, Elkhadem A. The Effect of Membrane Coverage on the Resorption of Autogenous Intraoral Block Grafts in Horizontal Ridge Augmentation: A Systematic Review of Literature and Meta-Analysis: Inevitability or an Iatrogenic Vulnerability? *J Evid Based Dent Pract.* 2018 Dec;18(4):275-289. [Medline: [30514442](#)] [doi: [10.1016/j.jebdp.2017.11.001](#)]
18. Antoun H, Sitbon JM, Martinez H, Missika P. A prospective randomized study comparing two techniques of bone augmentation: onlay graft alone or associated with a membrane. *Clin Oral Implants Res.* 2001 Dec;12(6):632-9. [Medline: [11737108](#)] [doi: [10.1034/j.1600-0501.2001.120612.x](#)]
19. Hämmerle CH, Karring T. Guided bone regeneration at oral implant sites. *Periodontol* 2000. 1998 Jun;17:151-75. [Medline: [10337322](#)] [doi: [10.1111/j.1600-0757.1998.tb00132.x](#)]
20. Rakhmatia YD, Ayukawa Y, Furuhashi A, Koyano K. Current barrier membranes: titanium mesh and other membranes for guided bone regeneration in dental applications. *J Prosthodont Res.* 2013 Jan;57(1):3-14. [Medline: [23347794](#)] [doi: [10.1016/j.jpor.2012.12.001](#)]
21. Arbab H, Greenwell H, Hill M, Morton D, Vidal R, Shumway B, Allan ND. Ridge Preservation Comparing a Nonresorbable PTFE Membrane to a Resorbable Collagen Membrane: A Clinical and Histologic Study in Humans. *Implant Dent.* 2016 Feb;25(1):128-34. [Medline: [26655097](#)] [doi: [10.1097/ID.0000000000000370](#)]
22. Dahlin C, Linde A, Gottlow J, Nyman S. Healing of bone defects by guided tissue regeneration. *Plast Reconstr Surg.* 1988 May;81(5):672-6. [Medline: [3362985](#)] [doi: [10.1097/00006534-198805000-00004](#)]
23. Kostopoulos L, Karring T. Augmentation of the rat mandible using guided tissue regeneration. *Clin Oral Implants Res.* 1994 Jun;5(2):75-82. [Medline: [7918912](#)] [doi: [10.1034/j.1600-0501.1994.050203.x](#)]
24. De Marco AC, Jardini MA, Lima LP. Revascularization of autogenous block grafts with or without an e-PTFE membrane. *Int J Oral Maxillofac Implants.* 2005 Nov-Dec;20(6):867-74. [Medline: [16392343](#)]
25. Khan SN, Cammisa FP Jr, Sandhu HS, Diwan AD, Girardi FP, Lane JM. The biology of bone grafting. *J Am Acad Orthop Surg.* 2005 Jan-Feb;13(1):77-86. [Medline: [15712985](#)] [doi: [10.5435/00124635-200501000-00010](#)]
26. Roca-Millan E, Jané-Salas E, Estrugo-Devesa A, López-López J. Evaluation of Bone Gain and Complication Rates after Guided Bone Regeneration with Titanium Foils: A Systematic Review. *Materials (Basel).* 2020 Nov 25;13(23):5346. [Medline: [33255825](#)] [PMC free article: [7728364](#)] [doi: [10.3390/ma13235346](#)]
27. Wessing B, Lettner S, Zechner W. Guided Bone Regeneration with Collagen Membranes and Particulate Graft Materials: A Systematic Review and Meta-Analysis. *Int J Oral Maxillofac Implants.* 2018 January/February;33(1):87–100. [Medline: [28938035](#)] [doi: [10.11607/jomi.5461](#)]
28. Jonker BP, Roeloffs MW, Wolvius EB, Pijpe J. The clinical value of membranes in bone augmentation procedures in oral implantology: [†] A systematic review of randomised controlled trials. *Eur J Oral Implantol.* 2016;9(4):335-365. [Medline: [27990504](#)]
29. Troiano G, Zhurakivska K, Lo Muzio L, Laino L, Cicciù M, Lo Russo L. Combination of bone graft and resorbable membrane for alveolar ridge preservation: A systematic review, meta-analysis, and trial sequential analysis. *J Periodontol.* 2018 Jan;89(1):46-57. [Medline: [28895779](#)] [doi: [10.1902/jop.2017.170241](#)]
30. Welch V, Petticrew M, Tugwell P, Moher D, O'Neill J, Waters E, White H; PRISMA-Equity Bellagio group. PRISMA-Equity 2012 extension: reporting guidelines for systematic reviews with a focus on health equity. *PLoS Med.* 2012;9(10):e1001333. [Medline: [23222917](#)] [PMC free article: [3484052](#)] [doi: [10.1371/journal.pmed.1001333](#)]
31. Liberati A, Altman DG, Tetzlaff J, Mulrow C, Gøtzsche PC, Ioannidis JP, Clarke M, Devereaux PJ, Kleijnen J, Moher D. The PRISMA statement for reporting systematic reviews and meta-analyses of studies that evaluate healthcare interventions: explanation and elaboration. *BMJ.* 2009 Jul 21;339:b2700. [Medline: [19622552](#)] [PMC free article: [2714672](#)] [doi: [10.1136/bmj.b2700](#)]
32. Higgins JPT AD, Sterne JAC (editors). Chapter 8: Assessing risk of bias in included studies. In: Higgins JPT, Churchill R, Chandler J, Cumpston MS (editors). *Cochrane Handbook for Systematic Reviews of Interventions* version 5.2.0 (updated June 2017) Cochrane, 2017. [URL: <http://handbook.cochrane.org/>]
33. Heberer S, Rühle B, Krekeler L, Schink T, Nelson JJ, Nelson K. A prospective randomized split-mouth study comparing iliac onlay grafts in atrophied edentulous patients: covered with periosteum or a bioresorbable membrane. *Clin Oral Implants Res.* 2009 Mar;20(3):319-26. [Medline: [19397644](#)] [doi: [10.1111/j.1600-0501.2008.01638.x](#)]
34. Moussa M, El-Dahab OA, El Nahass H. Anterior Maxilla Augmentation Using Palatal Bone Block with Platelet-Rich Fibrin: A Controlled Trial. *Int J Oral Maxillofac Implants.* 2016 May-Jun;31(3):708-15. [Medline: [27183079](#)] [doi: [10.11607/jomi.3926](#)]
35. Meijndert L, Raghoobar GM, Schüpbach P, Meijer HJ, Vissink A. Bone quality at the implant site after reconstruction of a local defect of the maxillary anterior ridge with chin bone or deproteinised cancellous bovine bone. *Int J Oral Maxillofac Surg.* 2005 Dec;34(8):877-84. [Medline: [15978776](#)] [doi: [10.1016/j.ijom.2005.04.017](#)]
36. Meijndert CM, Raghoobar GM, Meijndert L, Stellingsma K, Vissink A, Meijer HJ. Single implants in the aesthetic region preceded by local ridge augmentation; a 10-year randomized controlled trial. *Clin Oral Implants Res.* 2017 Apr;28(4):388-395. [Medline: [26919705](#)] [doi: [10.1111/clr.12811](#)]
37. Meijndert L, Raghoobar GM, Meijer HJ, Vissink A. Clinical and radiographic characteristics of single-tooth replacements preceded by local ridge augmentation: a prospective randomized clinical trial. *Clin Oral Implants Res.* 2008 Dec;19(12):1295-303. [Medline: [19040446](#)] [doi: [10.1111/j.1600-0501.2008.01523.x](#)]

38. Thor A, Wannfors K, Sennerby L, Rasmusson L. Reconstruction of the severely resorbed maxilla with autogenous bone, platelet-rich plasma, and implants: 1-year results of a controlled prospective 5-year study. *Clin Implant Dent Relat Res.* 2005;7(4):209-20. [Medline: [16336912](#)] [doi: [10.1111/j.1708-8208.2005.tb00066.x](#)]
39. Urban T, Kostopoulos L, Wenzel A. Immediate implant placement in molar regions: a 12-month prospective, randomized follow-up study. *Clin Oral Implants Res.* 2012 Dec;23(12):1389-97. [Medline: [22117841](#)] [doi: [10.1111/j.1600-0501.2011.02319.x](#)]
40. Chen ST, Darby IB, Adams GG, Reynolds EC. A prospective clinical study of bone augmentation techniques at immediate implants. *Clin Oral Implants Res.* 2005 Apr;16(2):176-84. [Medline: [15777327](#)] [doi: [10.1111/j.1600-0501.2004.01093.x](#)]
41. Wan X, Wang W, Liu J, Tong T. Estimating the sample mean and standard deviation from the sample size, median, range and/or interquartile range. *BMC Med Res Methodol.* 2014 Dec 19;14:135. [Medline: [25524443](#)] [PMC free article: [4383202](#)] [doi: [10.1186/1471-2288-14-135](#)]
42. Omar O, Elgali I, Dahlin C, Thomsen P. Barrier membranes: More than the barrier effect? *J Clin Periodontol.* 2019 Jun; 46 Suppl 21(Suppl Suppl 21):103-123. [Medline: [30667525](#)] [PMC free article: [6704362](#)] [doi: [10.1111/jcpe.13068](#)]
43. Albrektsson T, Zarb G, Worthington P, Eriksson AR. The long-term efficacy of currently used dental implants: a review and proposed criteria of success. *Int J Oral Maxillofac Implants.* 1986 Summer;1(1):11-25. [Medline: [3527955](#)]
44. Aludden H, Mordenfeld A, Cederlund A, Dahlin C, Spin-Neto R, Veiss-Pedersen P, Sritharan B, Starch-Jensen T. Radiographic changes in height and volume after lateral GBR procedures with different ratios of deproteinized bovine bone mineral and autogenous bone at different time points. An experimental study. *Clin Oral Implants Res.* 2021 Feb;32(2):167-179. [Medline: [33217060](#)] [doi: [10.1111/clar.13687](#)]
45. Hartlev J, Spin-Neto R, Schou S, Isidor F, Nørholt SE. Cone beam computed tomography evaluation of staged lateral ridge augmentation using platelet-rich fibrin or resorbable collagen membranes in a randomized controlled clinical trial. *Clin Oral Implants Res.* 2019 Mar;30(3):277-284. [Medline: [30715758](#)] [doi: [10.1111/clar.13413](#)]
46. Dasmah A, Thor A, Ekestubbe A, Sennerby L, Rasmusson L. Particulate vs. block bone grafts: three-dimensional changes in graft volume after reconstruction of the atrophic maxilla, a 2-year radiographic follow-up. *J Craniomaxillofac Surg.* 2012 Dec;40(8):654-9. [Medline: [22137760](#)] [doi: [10.1016/j.jcms.2011.10.032](#)]
47. Sbordone L, Toti P, Menchini-Fabris GB, Sbordone C, Piombino P, Guidetti F. Volume changes of autogenous bone grafts after alveolar ridge augmentation of atrophic maxillae and mandibles. *Int J Oral Maxillofac Surg.* 2009 Oct;38(10): 1059-65. [Medline: [19632815](#)] [doi: [10.1016/j.ijom.2009.06.024](#)]
48. Zizzari VL, Zara S, Tetè G, Vinci R, Gherlone E, Cataldi A. Biologic and clinical aspects of integration of different bone substitutes in oral surgery: a literature review. *Oral Surg Oral Med Oral Pathol Oral Radiol.* 2016 Oct;122(4):392-402. [Medline: [27496576](#)] [doi: [10.1016/j.oooo.2016.04.010](#)]
49. Murphy CM, O'Brien FJ, Little DG, Schindeler A. Cell-scaffold interactions in the bone tissue engineering triad. *Eur Cell Mater.* 2013 Sep 20;26:120-32. [Medline: [24052425](#)] [doi: [10.22203/eCM.v026a09](#)]
50. Acocella A, Bertolai R, Colafranceschi M, Sacco R. Clinical, histological and histomorphometric evaluation of the healing of mandibular ramus bone block grafts for alveolar ridge augmentation before implant placement. *J Craniomaxillofac Surg.* 2010 Apr;38(3):222-30. [Medline: [19648020](#)] [doi: [10.1016/j.jcms.2009.07.004](#)]
51. Zerbo IR, de Lange GL, Joldersma M, Bronckers AL, Burger EH. Fate of monocortical bone blocks grafted in the human maxilla: a histological and histomorphometric study. *Clin Oral Implants Res.* 2003 Dec;14(6):759-66. [Medline: [15015953](#)] [doi: [10.1046/j.0905-7161.2003.00967.x](#)]
52. Spin-Neto R, Stavropoulos A, Coletti FL, Faeda RS, Pereira LA, Marcantonio E Jr. Graft incorporation and implant osseointegration following the use of autologous and fresh-frozen allogeneic block bone grafts for lateral ridge augmentation. *Clin Oral Implants Res.* 2014 Feb;25(2):226-33. [Medline: [23346871](#)] [doi: [10.1111/clar.12107](#)]
53. Jensen T, Schou S, Stavropoulos A, Terheyden H, Holmstrup P. Maxillary sinus floor augmentation with Bio-Oss or Bio-Oss mixed with autogenous bone as graft: a systematic review. *Clin Oral Implants Res.* 2012 Mar;23(3): 263-73. [Medline: [21443592](#)] [doi: [10.1111/j.1600-0501.2011.02168.x](#)]
54. Pjetursson BE, Karoussis I, Bürgin W, Brägger U, Lang NP. Patients' satisfaction following implant therapy. A 10-year prospective cohort study. *Clin Oral Implants Res.* 2005 Apr;16(2):185-93. [Medline: [15777328](#)] [doi: [10.1111/j.1600-0501.2004.01094.x](#)]
55. Matthys C, Vervaeke S, Besseler J, De Bruyn H. Five-year study of mandibular overdentures on stud abutments: Clinical outcome, patient satisfaction and prosthetic maintenance-Influence of bone resorption and implant position. *Clin Oral Implants Res.* 2019 Sep;30(9):940-951. [Medline: [31264259](#)] [doi: [10.1111/clar.13501](#)]
56. Vipattanaporn P, Mattheos N, Pisarturakit P, Pimkhaokham A, Subbalekha K. Post-treatment patient-reported outcome measures in a group of Thai dental implant patients. *Clin Oral Implants Res.* 2019 Sep;30(9):928-939. [Medline: [31254435](#)] [doi: [10.1111/clar.13500](#)]
57. Tay JRH, Lu XJ, Lai WMC, Fu JH. Clinical and histological sequelae of surgical complications in horizontal guided bone regeneration: a systematic review and proposal for management. *Int J Implant Dent.* 2020 Nov 26;6(1):76. [Medline: [33241468](#)] [PMC free article: [7688776](#)] [doi: [10.1186/s40729-020-00274-y](#)]

To cite this article:

Gorgis R, Qazo L, Bruun NH, Starch-Jensen T.

Lateral Alveolar Ridge Augmentation with an Autogenous Bone Block Graft Alone with or without Barrier Membrane Coverage: a Systematic Review and Meta-Analysis

J Oral Maxillofac Res 2021;12(3):e1

URL: <http://www.ejomr.org/JOMR/archives/2021/3/e1/v12n3e1.pdf>

doi: [10.5037/jomr.2021.12301](https://doi.org/10.5037/jomr.2021.12301)

Copyright © Gorgis R, Qazo L, Bruun NH, Starch-Jensen T. Published in the JOURNAL OF ORAL & MAXILLOFACIAL RESEARCH (<http://www.ejomr.org>), 30 September 2021.

This is an open-access article, first published in the JOURNAL OF ORAL & MAXILLOFACIAL RESEARCH, distributed under the terms of the [Creative Commons Attribution-Noncommercial-No Derivative Works 3.0 Unported License](https://creativecommons.org/licenses/by-nc-nd/3.0/), which permits unrestricted non-commercial use, distribution, and reproduction in any medium, provided the original work and is properly cited. The copyright, license information and link to the original publication on (<http://www.ejomr.org>) must be included.

Appendix 1. PubMed search until the 8th of February 2021

Search	Query	Results
#32	Search: (((((((("Alveolar Ridge Augmentation"[Mesh]) OR (alveolar augmentation*[Text Word])) OR (alveolar ridge augmentation*[Text Word])) OR (lateral ridge augmentation*[Text Word])) OR (lateral augmentation*[Text Word])) OR (horizontal ridge augmentation*[Text Word])) OR (horizontal augmentation*[Text Word])) AND (((((((("Bone Transplantation"[Mesh]) OR (bone block*[Text Word])) OR (block graft*[Text Word])) OR (bone graft*[Text Word])) OR ("Transplantation, Autologous"[Mesh])) OR (autograft*[Text Word])) OR (autologous transplant*[Text Word])) OR (autogenous transplant*[Text Word])) OR (autogenous graft*[Text Word])) OR (autologous graft*[Text Word])) AND (((("Membranes, Artificial"[Mesh]) OR ("Membranes"[Mesh])) OR (membrane*[Text Word])) OR ("Platelet-Rich Plasma"[Mesh])) OR (platelet-rich*[Text Word] OR fibrin*[Text Word])) AND (((("Controlled Clinical Trial"[Publication Type] OR "Controlled Clinical Trials as Topic"[Mesh])) OR ((random*[Text Word] OR controlled[Text Word] OR crossover[Text Word] OR cross-over[Text Word] OR blind*[Text Word] OR mask*[Text Word])) AND (trial[Text Word] OR trials[Text Word] OR study[Text Word] OR studies[Text Word] OR analys*[Text Word] OR analyz*[Text Word])) OR rct[Text Word] OR ((singl*[Text Word] OR doubl*[Text Word] OR tripl*[Text Word])) AND (blind[Text Word] OR mask[Text Word])) OR placebo[Text Word]) Sort by: Publication Date	193
#31	Search: (((("Controlled Clinical Trial"[Publication Type] OR "Controlled Clinical Trials as Topic"[Mesh])) OR ((random*[Text Word] OR controlled[Text Word] OR crossover[Text Word] OR cross-over[Text Word] OR blind*[Text Word] OR mask*[Text Word])) AND (trial[Text Word] OR trials[Text Word] OR study[Text Word] OR studies[Text Word] OR analys*[Text Word] OR analyz*[Text Word])) OR rct[Text Word] OR ((singl*[Text Word] OR doubl*[Text Word] OR tripl*[Text Word])) AND (blind[Text Word] OR mask[Text Word])) OR placebo[Text Word] Sort by: Publication Date	1,868,552
#30	Search: (((((((("Alveolar Ridge Augmentation"[Mesh]) OR (alveolar augmentation*[Text Word])) OR (alveolar ridge augmentation*[Text Word])) OR (lateral ridge augmentation*[Text Word])) OR (lateral augmentation*[Text Word])) OR (horizontal ridge augmentation*[Text Word])) OR (horizontal augmentation*[Text Word])) AND (((((((("Bone Transplantation"[Mesh]) OR (bone block*[Text Word])) OR (block graft*[Text Word])) OR (bone graft*[Text Word])) OR ("Transplantation, Autologous"[Mesh])) OR (autograft*[Text Word])) OR (autologous transplant*[Text Word])) OR (autogenous transplant*[Text Word])) OR (autogenous graft*[Text Word])) OR (autologous graft*[Text Word])) AND (((("Membranes, Artificial"[Mesh]) OR ("Membranes"[Mesh])) OR (membrane*[Text Word])) OR ("Platelet-Rich Plasma"[Mesh])) OR (platelet-rich*[Text Word] OR fibrin*[Text Word])) Sort by: Publication Date	787
#29	Search: (((("Membranes, Artificial"[Mesh]) OR ("Membranes"[Mesh])) OR (membrane*[Text Word])) OR ("Platelet-Rich Plasma"[Mesh])) OR (platelet-rich*[Text Word] OR fibrin*[Text Word]) Sort by: Publication Date	1,748,294
#28	Search: platelet-rich*[Text Word] OR fibrin*[Text Word] Sort by: Publication Date	167,108
#27	Search: "Platelet-Rich Plasma"[Mesh] Sort by: Most Recent	4,644
#26	Search: membrane*[Text Word] Sort by: Publication Date	1,332,150
#25	Search: "Membranes"[Mesh] Sort by: Publication Date	330,130
#23	Search: "Membranes, Artificial"[Mesh] Sort by: Publication Date	102,876
#21	Search: (((((((("Bone Transplantation"[Mesh]) OR (bone block*[Text Word])) OR (block graft*[Text Word])) OR (bone graft*[Text Word])) OR ("Transplantation, Autologous"[Mesh])) OR (autograft*[Text Word])) OR (autologous transplant*[Text Word])) OR (autogenous transplant*[Text Word])) OR (autogenous graft*[Text Word])) OR (autologous graft*[Text Word]) Sort by: Publication Date	106,578
#20	Search: autologous graft*[Text Word] Sort by: Publication Date	1,348
#19	Search: autogenous graft*[Text Word] Sort by: Publication Date	798
#18	Search: autogenous transplant*[Text Word] Sort by: Publication Date	149
#17	Search: autologous transplant*[Text Word] Sort by: Publication Date	4,346
#16	Search: autograft*[Text Word] Sort by: Publication Date	19,360
#15	Search: "Transplantation, Autologous"[Mesh] Sort by: Most Recent	50,570
#13	Search: bone graft*[Text Word] Sort by: Publication Date	28,192
#12	Search: block graft*[Text Word] Sort by: Publication Date	445
#11	Search: bone block*[Text Word] Sort by: Publication Date	1,593
#10	Search: "Bone Transplantation"[Mesh] Sort by: Most Recent	32,165
#8	Search: (((((((("Alveolar Ridge Augmentation"[Mesh]) OR (alveolar augmentation*[Text Word])) OR (alveolar ridge augmentation*[Text Word])) OR (lateral ridge augmentation*[Text Word])) OR (lateral augmentation*[Text Word])) OR (horizontal ridge augmentation*[Text Word])) OR (horizontal augmentation*[Text Word]))	4,586
#7	Search: horizontal augmentation*[Text Word]	66
#6	Search: horizontal ridge augmentation*[Text Word]	90
#5	Search: lateral augmentation*[Text Word]	57
#4	Search: lateral ridge augmentation*[Text Word]	77
#3	Search: alveolar ridge augmentation*[Text Word]	4,507
#2	Search: alveolar augmentation*[Text Word]	67
#1	Search: "Alveolar Ridge Augmentation"[Mesh] Sort by: Most Recent	4,308

Appendix 2. Embase search until the 8th of February 2021

No.	Query	Results
#28	#22 AND #27	105
#27	#23 OR #24 OR #25 OR #26	8708749
#26	(((single OR double OR triple) NEAR/2 (blind* OR mask*)):ti,ab,de) OR placebo:ti,ab,de	611495
#25	(((random* OR controlled* OR crossover OR 'cross over' OR blind* OR mask*) NEAR/3 (trial* OR study OR studies OR analy*)):ti,ab,de) OR rct:ti,ab,de	8553156
#24	'controlled clinical trial'/exp	816422
#23	'randomized controlled trial'/exp	643616
#22	#3 AND #16 AND #21	356
#21	#17 OR #18 OR #19 OR #20	2117902
#20	'platelet-rich*' OR fibrin*	252821
#19	'thrombocyte rich plasma'/exp	13864
#18	'membrane*'	1503622
#17	'membrane'/exp	918541
#16	#4 OR #5 OR #6 OR #7 OR #8 OR #9 OR #10 OR #11 OR #12 OR #13 OR #14 OR #15	97271
#15	'autograft'/de	13994
#14	'autogenous graft*'	899
#13	'autologous graft*'	1826
#12	'autogenous transplant*'	161
#11	'autologous transplant*'	7894
#10	autograft*	28230
#9	'block graft*'	464
#8	'bone block*'	1777
#7	'bone transplantation'/exp	55687
#6	'bone graft*'	46585
#5	'bone graft'/exp	36000
#4	'autogenous bone graft'/de	20
#3	#1 OR #2	1651
#2	(alveolar OR lateral OR horizontal) NEXT/2 augmentation*	1651
#1	'alveolar ridge augmentation'/de	862

Appendix 3. Cochrane search until the 8th of February 2021

ID	Search	Hits
#1	MeSH descriptor: [Alveolar Ridge Augmentation] explode all trees	353
#2	((alveolar OR lateral OR horizontal) NEXT/2 augmentation*):ti,ab,kw	450
#3	#1 or #2	450
#4	MeSH descriptor: [Bone Transplantation] explode all trees	978
#5	("bone grafting"):ti,ab,kw	584
#6	(autografting):ti,ab,kw	183
#7	MeSH descriptor: [Transplantation, Autologous] explode all trees	1612
#8	(autologous transplantation):ti,ab,kw	5942
#9	(autogenous transplantation):ti,ab,kw	391
#10	(autologous graft):ti,ab,kw	1581
#11	(autogenous graft):ti,ab,kw	603
#12	(bone block):ti,ab,kw	1058
#13	(block graft):ti,ab,kw	455
#14	{OR #4-#13}	9321
#15	MeSH descriptor: [Membranes] explode all trees	5652
#16	MeSH descriptor: [Membranes, Artificial] explode all trees	1228
#17	(membrane):ti,ab,kw	13826
#18	MeSH descriptor: [Platelet-Rich Plasma] explode all trees	511
#19	(platelet-rich OR fibrin):ti,ab,kw	5471
#20	{OR #15-#19}	24358
#21	#3 and #14 and #20 in Trials (Word variations have been searched)	112

Appendix 4. Overview of the search until the 8th of February 2021

Database	Interface	Results	Date
PubMed	PubMed.gov	193	08.02.2021
Embase	Embase.com	105	08.02.2021
Cochrane Library	Wiley	112	08.02.2021
All	-	410	-
After duplicate removal with EndNote	-	234	-