

Is Surgical Removal of Asymptomatic Third Molars in the Horizontal III-C Position Advisable? A Pilot Study of Tomographic Evaluation

João Paulo da Silva Guilherme¹, Marcelo Santos Bahia¹, Yuri de Lima Medeiros², Marcella Yumi Kadooka³, Marcelo Tarcísio Martins⁴, Isabel Cristina Gonçalves Leite⁵, Marcos Vinicius Queiroz de Paula¹

¹Department of Basic and Oral Biology, Ribeirão Preto School of Dentistry, University of São Paulo, Ribeirão Preto, SP, Brazil.

²Department of Oral and Maxillofacial Surgery and Periodontology, Ribeirão Preto School of Dentistry, University of São Paulo, Ribeirão Preto, SP, Brazil.

³Department of Stomatology, School of Dentistry, São Paulo University, São Paulo, SP, Brazil.

⁴Faculty of Medical and Health Sciences of Juiz de Fora, Juiz de Fora, MG, Brazil.

⁵Department of Public Health, School of Medicine, Federal University of Juiz de Fora, Juiz de Fora, MG, Brazil.

⁶Department of Dental Clinic, School of Dentistry, Federal University of Juiz de Fora, Juiz de Fora, MG, Brazil.

Corresponding Author:

Marcelo Santos Bahia

Department of Oral and Maxillofacial Surgery and Periodontology
School of Dentistry of Ribeirão Preto, University of São Paulo (FORP-USP)
Cafe Ave, S/N, West Sub-sector, 14040-904, Ribeirão Preto, São Paulo
Brazil

Phone: +55 16 99746 0033

E-mail: marcelosbahia@usp.br

ABSTRACT

Objectives: This cross-sectional study aimed to measure the distance between the buccal and lingual cortical bones and its relation with the mandibular canal roof of third molars classified as III-C position according to Winter, Pell and Gregory classifications in cone-beam computed tomography.

Material and Methods: A total of 140 lower third molars were classified according to Winter, Pell and Gregory. The distance between the buccal external cortex and the lingual external cortex was measured at 25%, 50% and 75% of the distance to the roof of the mandibular canal in parasagittal sections of teeth classified in horizontal III-C position. The presence or absence of lesions associated with the elements in this position was observed. Descriptive statistical analysis was performed and the intra-examiner agreement was calculated using the Bland-Altman and t-test methods (0.88 and 0.91, respectively). The significance level used was 5% ($P \leq 0.05$).

Results: Seventy patients (29.4 [SD 8.8] years, 54% women and 46% men) were included. Fourteen (10%) third molars were classified in horizontal III-C position. The average measurements taken were 1.78, 1.1 and 1.53 mm for the distances between the buccal external cortex and lingual external cortex, at 25%, 50% and 75% of the distance to the roof of the mandibular canal, respectively. No pathological conditions associated with the included elements were observed.

Conclusions: Analysis of cone-beam computed tomography parasagittal sections of third molars classified in horizontal III-C position, revealed proximity of impacted teeth to the mandibular canal roof, mainly in the midline between the buccal and lingual external cortices.

Keywords: cone-beam computed tomography; impacted teeth; third molar.

Accepted for publication: 29 September 2024

To cite this article:

Guilherme JPS, Bahia MS, Medeiros YL, Kadooka MY, Martins MT, Leite ICG, de Paula MVQ.

Is Surgical Removal of Asymptomatic Third Molars in the Horizontal III-C Position Advisable? A Pilot Study of Tomographic Evaluation

J Oral Maxillofac Res 2024;15(3):e4

URL: <http://www.ejomr.org/JOMR/archives/2024/3/e4/v15n3e4.pdf>

doi: [10.5037/jomr.2024.15304](https://doi.org/10.5037/jomr.2024.15304)

INTRODUCTION

Imaging exams are essential for adequate surgical planning and complication reduction during the extraction of impacted third molars [1,2]. Panoramic radiography is the most widely used method to check the proximity of the roots of the lower third molars and the mandibular canal. However, it presents limitations such as distortions, superimposition, variable magnification in the image and bi-dimensionality [2-4]. With the technological advance, cone-beam computed tomography (CBCT) began to be chosen for planning the more complex extraction procedures once it allowed the three-dimensional visualization of the structures and the image reconstruction, besides determining the distance and inclination of adjacent structures [5,6].

In 1926, George Winter classified these teeth regarding their angulations [7] and in 1933, Pell and Gregory classified them regarding their depth of impact and their association with the mandibular ramus [8], making it easier for the professionals to communicate and allowing better surgical predictability [1,9,10]. Lower third molars in the III-C horizontal position are the teeth inside the mandibular ramus, inferior to the cervical line of the second molar and in the horizontal angulation [7,8]. Being in intimate contact with the mandibular canal [10], these teeth require more experience and an in-depth knowledge of the local anatomy for the professional to choose whether to extract them or not [11].

Even though many authors have made tomographic measurements searching for a deeper comprehension of possible injuries to the inferior alveolar nerve during third molar extractions [12-14], no study ever proposed to categorize and evaluate especially third molars in the III-C horizontal position.

This cross-sectional study aimed to measure the distance between the buccal and lingual cortical bones and its relation with the mandibular canal roof of third molars classified as III-C horizontal in cone-beam computed tomography, assisting in the choice of extraction or maintenance or preservation of these teeth.

MATERIAL AND METHODS

Study design and settings

It is a cross-sectional study that evaluated CBCT exams from the digital image database of the School of Dentistry of the Federal University of Juiz de Fora (Juiz de Fora, Minas Gerais, Brazil). This research

was approved by the Research Ethics Committee of Federal University of Juiz de Fora (Juiz de Fora, MG, Brazil), under process no. 2.631.1601/2018.

All procedures followed were in accordance with the ethical standards of the responsible committee on human experimentation (institutional and national) and with the Helsinki Declaration of 1975, as revised in 2008.

Participant selection

Imaging exams of patients over 18 years old who had bilateral lower third molars were included. Images presenting metallic artefacts, craniofacial anomalies, facial fractures and third molars with incomplete rhizogenesis were excluded. Data were collected from August 1, 2023 to September 1, 2023.

Tomographic assessment

All images were obtained using the same CBCT device (i-Cat® - Imaging Sciences International; Hatfield, PA, USA), with the following acquisition protocol: 120 kV, 08 mA, 26.9 s, 0.25 mm voxel size, and field of view (FOV) 7 x 13 cm. The XSTD files (XoranCAT Study File) of the tomographic images were stored and converted by i-Cat by Xoran software (Xoran CAT, v. 3.0.34, Xoran technologies; Ann Arbor, MI, USA) into DICOM files (Digital Imaging and Communications in Medicine). After obtaining the DICOM files, the images were converted to the ImplantViewer® version 3.0 image processing software (Anne Solutions; São Paulo, SP, Brazil).

Initially, in panoramic reconstruction, the lower third molars were classified according to Winter [7], Pell and Gregory [8]. Classification based on the extent of the third molar covered by the mandibular ramus was as follows:

- Class I - the mesiodistal diameter of the third molar is shorter than the distance between the anterior border of the mandibular ramus and the distal surface of the second molar.
- Class II - the mesiodistal diameter of the third molar is greater than the distance between the anterior border of the mandibular ramus and the distal surface of the second molar.
- Class III - there is no space between the distal surface of the second molar and the mandibular ramus.

Additionally, classification based on the height of the occlusal plane of the adjacent second molar was defined as:

- Position A - the occlusal surface of the third molar is at or above the level of the occlusal plane

of the second molar.

- Position B - the occlusal surface of the third molar is located between the occlusal plane and the cervical portion of the second molar.
- Position C - the occlusal surface of the third molar is below the cervical portion of the second molar.

Furthermore, based on the long axis of the second molar, the following classifications were applied:

- Vertical - the axis of the mandibular third molar is parallel to the mandibular second molar.
- Mesioangulated - the long axis of the mandibular third molar is directed towards the mesial direction in relation to the second molar.
- Horizontal - the long axis of the mandibular third molar is perpendicular to the second molar.
- Distoangulated - the long axis of the mandibular third molar is directed to the distal position in relation to the second molar.
- Inverted - the crown of the third molar is facing the base of the mandible, while the root is directed towards the occlusal plane.

Subsequently, the teeth classified in the horizontal III-C position were identified on panoramic radiographs and then evaluated in parasagittal sections on CBCT. Measurements were taken of the distance between the buccal external cortex and the lingual external cortex at 25%, 50%, and 75% of the distance to the roof of the mandibular canal (Figure 1). Additionally, the presence or absence of injury associated with the elements in this position was evaluated.

Sample evaluation

The measurements were made by a professional (J.P.S.G.), trained and calibrated in a pilot test by a specialist in dental radiology (M.V.Q.P.) with more than 20 years of experience, using a sample not included in this study. All assessments were carried out on a 21.5-inch LCD monitor Dell S2240L (Dell Computadores do Brasil Ltda, Rio Grande do Sul, Brazil) with high-definition resolution (1920 x 1080 pixels), located in a room under dimly lit conditions. A limit of 20 daily assessments was established to avoid eye strain and loss of analysis. The brightness and zoom of the images could be adjusted using the ImplantViewer® (Anne Solutions) software to improve the visualization of the analysed structures. Fifty per cent of the sample was re-evaluated after 15 days to determine intra-examiner agreement.

Statistical analysis

A descriptive statistical analysis was performed to obtain the average, standard deviation (SD), absolute and relative frequencies. The calculation of intra-examiner agreement was performed using the Bland-Altman method and intraclass correlation coefficient (ICC). Fisher's one-tailed comparison of proportions and the t-test for comparison of means were also utilized. IBM SPSS version 21.0 (Statistical Package for the Social Sciences, IBM Corp, Armonk, NY, USA) software was used for the analysis. The significance level used was 5% ($P \leq 0.05$).

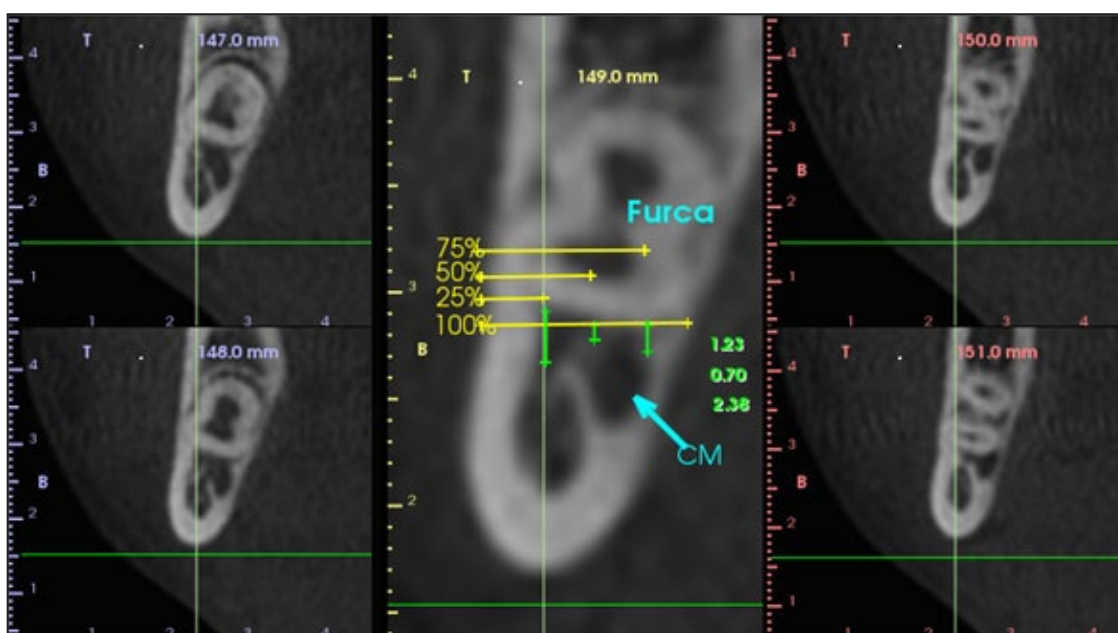


Figure 1. Tomographic analysis in parasagittal cuts of the third molar in III-C horizontal position and its respectively measurements made at 25%, 50% and 75% from the buccal external cortex to the lingual external cortex to the mandibular canal roof. CM = mandibular canal; furca = furcation.

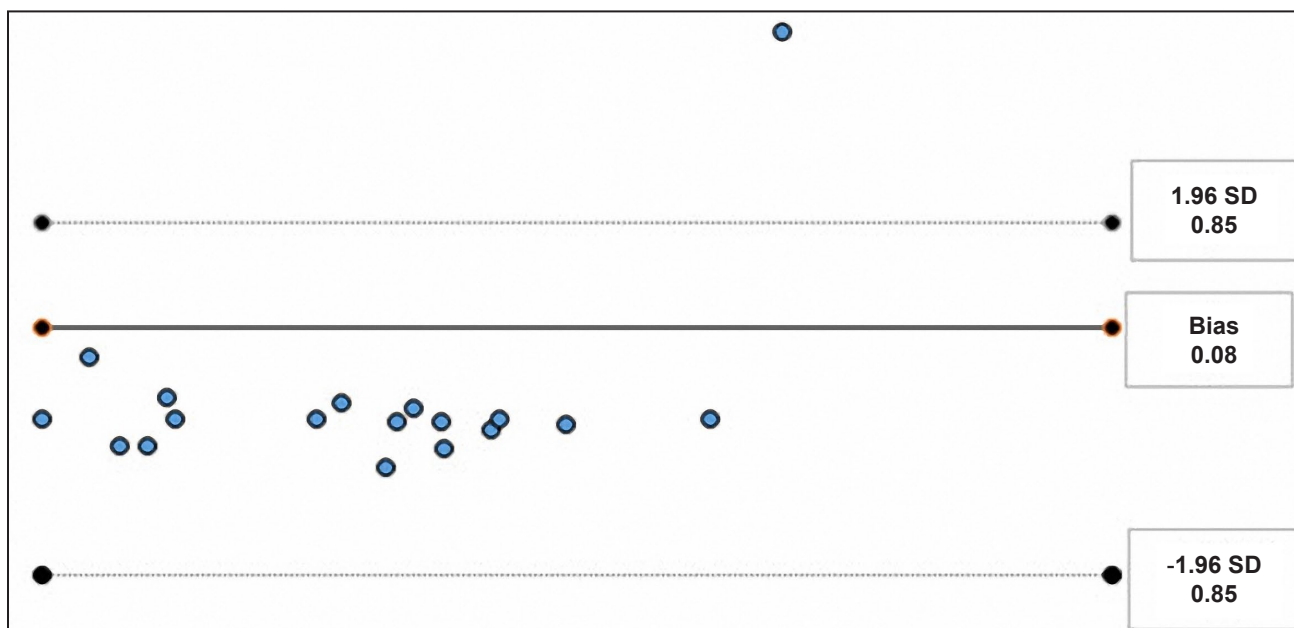


Figure 2. Agreement by the Bland and Altman graph for the dispersion of average errors of continuous variables in the two measurements carried out within a 15-day interval.

RESULTS

A hundred and forty lower third molars were evaluated in tomographic sections (70 on the right side and 70 on the left side) obtained from 70 patients: 38 women and 32 men (54% women and 46% men). The patient’s age ranged from 19 to 60, with an average of 29.41 (SD 8.8) years old. No significant statistical differences were observed between the measurements taken within a 15-day interval to assess concordance using t-test ($P = 0.425$) and Bland and Altman methods (Figure 2). The inter-examiner and intra-examiner concordances (ICC) were 0.88 and 0.91, respectively, which are considered excellent.

Among the 140 third molars, 99 (70.7%) were classified. The majority of the third molars on the left side were classified as III-B horizontal ($n = 7$), II-A vertical ($n = 6$) and III-C horizontal ($n = 6$), while the most prevalent classifications on the right side were III-B horizontal ($n = 11$) and III-C horizontal ($n = 8$) (Table 1).

Fourteen third molars (10%) were classified as III-C horizontal. The total average of the measurements taken was 1.78, 1.1 and 1.53 mm for the distances from the buccal external cortex to the lingual external cortex at 25%, 50% and 75% of the distance to the roof of the mandibular canal, respectively (Table 2). Great proximity between the structures evaluated was demonstrated, mainly at a 50% distance, alerting the professional about a greater chance of causing injury to the inferior alveolar nerve during surgical techniques for its removal. No pathological conditions

Table 1. Lower third molars classification according to Winter [1], Pell and Gregory [8], in the same sample ($n = 70$)

Winter, Pell and Gregory classification	Left		Right		P-value ^a
	N	%	N	%	
I-A vertical	4	5.71	4	5.71	0.32
I-A mesioangular	1	1.43	3	4.29	0.7
II-A vertical	6	8.57	1	1.43	0.69
II-A mesioangular	2	2.86	2	2.86	0.19
II-A distoangular	1	1.43	4	5.71	0.32
II-B vertical	1	1.43	3	4.29	0.19
II-B mesioangular	4	5.71	1	1.43	0.51
II-B horizontal	2	2.86	1	1.43	0.19
II-C mesioangular	1	1.43	4	5.71	0.72
III-A mesioangular	1	1.43	1	1.43	0.51
III-A horizontal	2	2.86	1	1.43	0.72
III-B vertical	1	1.43	1	1.43	0.72
III-B mesioangular	4	5.71	4	5.71	0.64
III-B horizontal	7	10	11	15.71	0.23
III-C mesioangular	4	5.71	3	4.29	0.51
III-C horizontal	6	8.57	8	11.43	0.41
Could not be classified	23	32.86	18	25.71	0.31
Total	70	100	70	100	-

^aFisher’s exact test, significant at the level $P \leq 0.05$.

associated with the third molar were observed in the horizontal III-C classification.

The measurements on the right side showed an average of 1.95 mm at 25%, 1.3 mm at 50%, and 1.78 mm at 75%, with significant variability reflected by the standard deviations. This indicates a close

Table 2. Measurements made in the teeth classified as III-C horizontal 25%, 50% and 75% distant of the buccal external cortex to the lingual external cortex to the mandibular canal roof

Side	No.	Distance (mm)			P-value ^a
		25%	50%	75%	
Right	1	2.91	1.45	1.87	0.41
	2	0	0	0	0.67
	3	1.23	0.26	1.06	0.1
	4	1.55	1.84	1.55	0.03
	5	1.85	0.34	1.43	0.11
	6	2.87	2.62	3.77	0.01
	7	1.83	1.11	1.17	0.27
	8	3.4	2.8	3.4	0.04
	Mean (SD)	1.95 (1.1)	1.3 (1.1)	1.78 (1.2)	0.02
Left	1	1.11	0.39	0.78	0.07
	2	1.99	0.87	1.11	0.06
	3	4.58	2.17	4.58	0.14
	4	0	0	0	-
	5	1.32	1.32	0.16	0.01
	6	0.76	0.76	1.06	0.01
	Mean (SD)	1.63 (1.6)	0.91 (0.7)	1.28 (1.7)	0.16

^at-test, significant at the level $P \leq 0.05$.
SD = standard deviation.

proximity to the mandibular canal, particularly concerning at the 50% mark, where the P-value of 0.02 suggests a statistically significant risk of inferior alveolar nerve injury. On the left side, the averages were slightly lower: 1.63 mm at 25%, 0.91 mm at 50%, and 1.28 mm at 75%. Although these differences were not statistically significant overall ($P = 0.16$).

DISCUSSION

The surgical technique for extracting impacted lower third molars must be cautious and judicious due to some factors, such as clinical experience [11], proximity to vitally important structures, impaction index, limited field of vision related to its position and the different angles of these elements. All of these factors must be taken into consideration when deciding whether it is appropriate to extract these teeth [15,16]. The greater the degree of impaction of the third molar, the greater the degree of extraction difficulty and risks, requiring procedures such as osteotomy and odontosection [1,9]. In a study with 1055 lower third molars, the prevalence of the III-C position was 15%, while the horizontal position was 12.1% [17]. Our study found a prevalence of 15% and 27.1%, respectively.

The prevalence of postoperative complications associated with lower third molar extraction in a multicenter study with 1826 patients was 10% [10]. The most common complications are pain, swelling, trismus, infection, haemorrhage, periodontal injuries, dentoalveolar fractures, mandibular fractures and inferior alveolar nerve paraesthesia [10,18,19]. Inferior alveolar nerve injury leading to paraesthesia can occur during anaesthetic injection, intraoperative accidents, such as osteotomy, odontosection and alveolus curettage [20]. Some authors report a prevalence of injury to the inferior alveolar nerve during the removal of lower third molars, ranging from 1.3% to 5.9% [21] and 1.7% [10]. Pippi et al. [16] found temporary damage to the inferior alveolar nerve in 10.9% of cases after extraction of lower third molars that were overlapping the mandibular canal. The most common symptoms of this condition are numbness, itching, tingling, and altered sensitivity to cold and heat [20], with a duration ranging from 18 to 180 days [16]. Other authors also proposed to perform tomographic measurements in the lower third molar region, aiming to avoid causing damage to the inferior alveolar nerve. Amin et al. [12] found an average bone thickness of 1.25 mm at the level of the apex of these teeth, with a 12.3% prevalence of perforation of the lingual cortex by the root apex of impacted third molars at a horizontal angle. Srivastava et al. [13] found that the smallest average bilateral distance between the mandibular canal and the lingual cortex, buccal cortex and root apex was 1.47, 4.25 and 3.8 mm, respectively, in erupted lower third molars. Usha et al. [14] measured the distance from the vestibular cortical margin to the mandibular canal and found an average distance of 6.27 mm on the right side and 6.35 mm on the left side. Our study was the first to perform specific measurements of third molars in the horizontal III-C position. The results demonstrated great proximity between the structures evaluated, which could cause injuries to the inferior alveolar nerve during surgery. The indications for the impacted third molar removal include recurrent pericoronitis, carious lesions, pulpitis, cysts, tumours, root resorption of adjacent teeth, orthognathic surgery and orthodontic rehabilitation. The most common contraindications for removing these teeth include advanced age, high risk of damaging important structures, systemic involvement of the patient and absence of associated pathological signs and symptoms [22,23]. Haddad et al. [24] found a prevalence of 7.4% of pathological conditions related to impacted lower third molars, especially in vertical positions [7]

and III-C position according to Winter, Pell and Gregory classifications [8]. In our study, the presence of lesions associated with these teeth was not observed, possibly due to the small sample included.

Many professionals choose to perform the prophylactic extraction of impacted third molars to prevent possible future complications, although there are controversies regarding its indication [15,25]. For Friedman et al. [26], the removal of asymptomatic third molars without associated pathological conditions does not meet the standard of evidence-based practice since, in many cases, conservative treatment would solve the problem without exposing the patient to unnecessary risks of iatrogenic injuries. Shoshani-Dror et al. [25] and Vranck et al. [27] suggest that there are benefits in preventively extracting asymptomatic third molars, preferably in young patients, to avoid persistent morbidity and nerve complications. Anyanechi et al. [28] carried out a prospective study and observed that all second molars adjacent to impacted and asymptomatic third molars were free of caries and periodontal disease, with no indication for extraction. Marques et al. [29], however, found an increased prevalence of distal caries in second molars if the adjacent third molar was in a horizontal position, when the contact point was overlapping (45.8%) or below (47.0%) the cemento-enamel junction.

Friedman [26] also points out that, in the United States, the extraction of third molars has become a profitable market, generating around 3 billion dollars per year. Not performing prophylactic extractions would reduce the annual income of dental surgeons, which could drive the spread of misinformation and myths perpetuated by many professionals. The currently available evidence is controversial. Professionals must weigh the risks and benefits and use clinical experience to guide shared decision-making with patients who have impacted asymptomatic and disease-free third molars. If it is decided to preserve these teeth, periodical clinical evaluations are recommended to avoid undesirable results [15].

Among the limitations of this study, the small sample of patients with lower third molars in the horizontal III-C position can be mentioned. It is suggested that future studies carry out tomographic measurements on a larger number of patients and other populations, given that the sample in this study is exclusively Brazilian. The results of this study would also be better understood if the clinical condition of the observed teeth was known. One non-investigated aspect was whether the lack of other teeth could have affected the angulation of the third molars analysed. Despite the aforementioned limitations, this study provided reliable data and contributed to support scientific evidence in the decision to extract or maintain asymptomatic impacted teeth from a tomographic.

CONCLUSIONS

Analysis of cone-beam computed tomography parasagittal sections of third molars classified in horizontal III-C position, revealed proximity of impacted teeth to the mandibular canal roof, mainly in the midline between the buccal and lingual external cortices. Furthermore, no pathological conditions were found in the included elements. Therefore, regarding the tomographic aspects observed, preservation would be more suitable for asymptomatic third molars in the horizontal III-C position. However, the limitations and other non-analysed aspects of the study must also be considered, such as clinical conditions and possible injuries to adjacent second molars.

ACKNOWLEDGMENTS AND DISCLOSURE STATEMENTS

This research did not receive any specific grant from funding agencies in the public, commercial, or not-for-profit sectors. The authors declare that they have no known competing financial interests or personal relationships which could have appeared to influence the work reported in this article.

REFERENCES

1. Jeyashree T, Kumar MPS. Evaluation of difficulty index of impacted mandibular third molar extractions. *J Adv Pharm Technol Res.* 2022 Nov;13(Suppl 1):S98-S101. [Medline: [36643150](#)] [PMC free article: [9836111](#)] [doi: [10.4103/japtr.japtr_362_22](#)]
2. Machado AH, Freitas DQ, Fontenele RC, Farias-Gomes A, Francesquini Júnior L, Ambrosano GMB. Radiographic evaluation of mandibular third molars: an ex vivo comparative study between multilayer and conventional panoramic radiography. *Clin Oral Investig.* 2023 Nov;27(11):6451-6460. [Medline: [37728617](#)] [doi: [10.1007/s00784-023-05249-y](#)]

3. Atieh MA. Diagnostic accuracy of panoramic radiography in determining relationship between inferior alveolar nerve and mandibular third molar. *J Oral Maxillofac Surg.* 2010 Jan;68(1):74-82. [Medline: [20006158](#)] [doi: [10.1016/j.joms.2009.04.074](#)]
4. Sezgin ÖS, Kayipmaz S, Yasar D, Yilmaz AB, Ozturk MH. Comparative dosimetry of dental cone beam computed tomography, panoramic radiography, and multislice computed tomography. *Oral Radiol.* 2012 Dec; 28:32-7. [doi: [10.1007/s11282-011-0078-5](#)]
5. Moreira PEO, Normando D, Pinheiro LR, Brandão GAM. Prognosis for the impacted lower third molars: Panoramic reconstruction versus tomographic images. *Oral Surg Oral Med Oral Pathol Oral Radiol.* 2020 Dec;130(6):625-631. [Medline: [32981872](#)] [doi: [10.1016/j.oooo.2020.07.006](#)]
6. Wanzeler AMV, Silveira HLDD, Buligon RP, Corsetti A, Vieira HT, Arús NA, Vizzotto MB. Can CBCT change the level of confidence of oral maxillofacial surgeons in mandibular third molar management? *Braz Oral Res.* 2022 Jun 10;36:e078. [Medline: [35703704](#)] [doi: [10.1590/1807-3107bor-2022.vol36.0078](#)]
7. Pigott JP. Principles of Exodontia as Applied to the Impacted Mandibular Third Molar. *Yale J Biol Med.* 1928 Oct;1(1):63. [PMC free article: [2606205](#)]
8. Pell GJ, Gregory GT. Impacted third molars: classification and modified technique for removal. *Dent Digest.* 1933;39:330 -8.
9. Jaroń A, Trybek G. The Pattern of Mandibular Third Molar Impaction and Assessment of Surgery Difficulty: A Retrospective Study of Radiographs in East Baltic Population. *Int J Environ Res Public Health.* 2021 Jun 3;18(11):6016. [Medline: [34205078](#)] [PMC free article: [8199855](#)] [doi: [10.3390/ijerph18116016](#)]
10. Yamada SI, Hasegawa T, Yoshimura N, Hakoyama Y, Nitta T, Hirahara N, Miyamoto H, Yoshimura H, Ueda N, Yamamura Y, Okuyama H, Takizawa A, Nakanishi Y, Iwata E, Akita D, Itoh R, Kubo K, Kondo S, Hata H, Koyama Y, Miyamoto Y, Nakahara H, Akashi M, Kirita T, Shibuya Y, Umeda M, Kurita H. Prevalence of and risk factors for postoperative complications after lower third molar extraction: A multicenter prospective observational study in Japan. *Medicine (Baltimore).* 2022 Aug 12;101(32):e29989. [Medline: [35960058](#)] [PMC free article: [9371489](#)] [doi: [10.1097/MD.00000000000029989](#)]
11. Sánchez Jorge MI, Ocaña RA, Valle Rodríguez C, Peyró Fernández-Montes B, Rico-Romano C, Bazal-Bonelli S, Sánchez-Labrador L, Cortés-Bretón Brinkmann J. Mandibular third molar extraction: perceived surgical difficulty in relation to professional training. *BMC Oral Health.* 2023 Jul 14;23(1):485. [Medline: [37452399](#)] [PMC free article: [10349451](#)] [doi: [10.1186/s12903-023-03131-7](#)]
12. Amin SA, Elsheikh AK, Meyer RA, Bagheri SC. Incidence of Pre-Existing Lingual Cortex Perforation Before Removal of Mandibular Third Molars. *J Oral Maxillofac Surg.* 2020 Dec;78(12):2129-2137. [Medline: [32916133](#)] [doi: [10.1016/j.joms.2020.08.010](#)]
13. Srivastava S, Alharbi HM, Alharbi AS, Soliman M, Eldwakhly E, Abdelhafeez MM. Assessment of the Proximity of the Inferior Alveolar Canal with the Mandibular Root Apices and Cortical Plates-A Retrospective Cone Beam Computed Tomographic Analysis. *J Pers Med.* 2022 Oct 28;12(11):1784. [Medline: [36579488](#)] [PMC free article: [9694589](#)] [doi: [10.3390/jpm12111784](#)]
14. Usha AM, Thelekkat Y, John J, Nair R, Nazar J, Kumar DS. Evaluation of the Linear Relationship of the Inferior Alveolar Nerve Canal to the Lateral Cortex and the Alveolar Crest in the Posterior Mandible: A Computed Tomographic Study. *J Maxillofac Oral Surg.* 2024 Feb;23(1):68-74. [Medline: [38312975](#)] [PMC free article: [10830932](#)] [doi: [10.1007/s12663-023-02010-6](#)]
15. Ghaemina H, Nienhuijs ME, Toedtling V, Perry J, Tummers M, Hoppenreijts TJ, Van der Sanden WJ, Mettes TG. Surgical removal versus retention for the management of asymptomatic disease-free impacted wisdom teeth. *Cochrane Database Syst Rev.* 2020 May 4;5(5):CD003879. [Medline: [32368796](#)] [PMC free article: [7199383](#)] [doi: [10.1002/14651858.CD003879.pub5](#)]
16. Pippi R, De Luca S, Pietrantonio A. A Prospective Observational Study on the Variables Affecting the Risk of Inferior Alveolar Nerve Damage During Lower Third Molar Surgery With Nerve/Root Proximity. *J Oral Maxillofac Surg.* 2022 Jan;80(1):13-21. [Medline: [34582807](#)] [doi: [10.1016/j.joms.2021.08.162](#)]
17. Santos KK, Lages FS, Maciel CAB, Glória JCR, Douglas-de-Oliveira DW. Prevalence of Mandibular Third Molars According to the Pell & Gregory and Winter Classifications. *J Maxillofac Oral Surg.* 2022 Jun;21(2):627-633. [Medline: [35712399](#)] [PMC free article: [9192858](#)] [doi: [10.1007/s12663-020-01473-1](#)]
18. Gojaveva G, Tekin G, Saruhan Kose N, Dereci O, Kosar YC, Caliskan G. Evaluation of complications and quality of life of patient after surgical extraction of mandibular impacted third molar teeth. *BMC Oral Health.* 2024 Jan 25;24(1):131. [Medline: [38273294](#)] [PMC free article: [10811863](#)] [doi: [10.1186/s12903-024-03877-8](#)]
19. Sayed N, Bakathir A, Pasha M, Al-Sudairy S. Complications of Third Molar Extraction: A retrospective study from a tertiary healthcare centre in Oman. *Sultan Qaboos Univ Med J.* 2019 Aug;19(3):e230-e235. [Medline: [31728221](#)] [PMC free article: [6839670](#)] [doi: [10.18295/squmj.2019.19.03.009](#)]
20. Garcia-Blanco M, Gualtieri AF, Lovaglio-Rivas AC, Ruffini JM, Puia SA. Trigeminal nerve injuries. Four years' experience at a single Argentine referral center and a literature review. *Acta Odontol Latinoam.* 2021 Dec 31;34(3):263-270. [Medline: [35088814](#)] [PMC free article: [10315094](#)] [doi: [10.54589/aol.34/3/263](#)]

21. Rieder M, Remschmidt B, Schrepf V, Schwaiger M, Jakse N, Kirnbauer B. Neurosensory Deficits of the Mandibular Nerve Following Extraction of Impacted Lower Third Molars-A Retrospective Study. *J Clin Med*. 2023 Dec 13;12(24):7661. [Medline: [38137730](#)] [PMC free article: [10743649](#)] [doi: [10.3390/jcm12247661](#)]
22. Krishnan B, Sheikh MH, Rafa el-G, Orafi H. Indications for removal of impacted mandibular third molars: a single institutional experience in Libya. *J Maxillofac Oral Surg*. 2009 Sep;8(3):246-8. [Medline: [23139518](#)] [PMC free article: [3454225](#)] [doi: [10.1007/s12663-009-0060-5](#)]
23. Patel S, Mansuri S, Shaikh F, Shah T. Impacted Mandibular Third Molars: A Retrospective Study of 1198 Cases to Assess Indications for Surgical Removal, and Correlation with Age, Sex and Type of Impaction-A Single Institutional Experience. *J Maxillofac Oral Surg*. 2017 Mar;16(1):79-84. [Medline: [28286389](#)] [PMC free article: [5328873](#)] [doi: [10.1007/s12663-016-0929-z](#)]
24. Haddad Z, Khorasani M, Bakhshi M, Tofangchiha M, Shalli Z. Radiographic Position of Impacted Mandibular Third Molars and Their Association with Pathological Conditions. *Int J Dent*. 2021 Mar 24;2021:8841297. [Medline: [33833805](#)] [PMC free article: [8012125](#)] [doi: [10.1155/2021/8841297](#)]
25. Shoshani-Dror D, Shilo D, Ginini JG, Emodi O, Rachmiel A. Controversy regarding the need for prophylactic removal of impacted third molars: An overview. *Quintessence Int*. 2018;49(8):653-662. [Medline: [30109309](#)]
26. Friedman JW. The prophylactic extraction of third molars: a public health hazard. *Am J Public Health*. 2007 Sep;97(9):1554-9. [Medline: [17666691](#)] [PMC free article: [1963310](#)] [doi: [10.2105/AJPH.2006.100271](#)]
27. Vranckx M, Fieuws S, Jacobs R, Politis C. Prophylactic vs. Symptomatic third molar removal: effects on patient postoperative morbidity. *J Evid Based Dent Pract*. 2021 Sep;21(3):101582. [Medline: [34479679](#)] [doi: [10.1016/j.jebdp.2021.101582](#)]
28. Anyanechi CE, Saheeb BD, Okechi UC. Is prophylactic removal of impacted mandibular third molar justified in all patients? A prospective clinical study of patients 50 years and above. *Afr Health Sci*. 2019 Mar;19(1):1789-1794. [Medline: [31149009](#)] [PMC free article: [6531985](#)] [doi: [10.4314/ahs.v19i1.55](#)]
29. Marques J, Montserrat-Bosch M, Figueiredo R, Vilchez-Pérez MA, Valmaseda-Castellón E, Gay-Escoda C. Impacted lower third molars and distal caries in the mandibular second molar. Is prophylactic removal of lower third molars justified? *J Clin Exp Dent*. 2017 Jun 1;9(6):e794-e798. [Medline: [28638558](#)] [PMC free article: [5474337](#)] [doi: [10.4317/jced.53919](#)]

To cite this article:

Guilherme JPS, Bahia MS, Medeiros YL, Kadooka MY, Martins MT, Leite ICG, de Paula MVQ.

Is Surgical Removal of Asymptomatic Third Molars in the Horizontal III-C Position Advisable? A Pilot Study of Tomographic Evaluation

J Oral Maxillofac Res 2024;15(3):e4

URL: <http://www.ejomr.org/JOMR/archives/2024/3/e4/v15n3e4.pdf>

doi: [10.5037/jomr.2024.15304](https://doi.org/10.5037/jomr.2024.15304)

Copyright © Guilherme JPS, Bahia MS, Medeiros YL, Kadooka MY, Martins MT, Leite ICG, de Paula MVQ. Published in the JOURNAL OF ORAL & MAXILLOFACIAL RESEARCH (<http://www.ejomr.org>), 30 September 2024.

This is an open-access article, first published in the JOURNAL OF ORAL & MAXILLOFACIAL RESEARCH, distributed under the terms of the [Creative Commons Attribution-Noncommercial-No Derivative Works 3.0 Unported License](#), which permits unrestricted non-commercial use, distribution, and reproduction in any medium, provided the original work and is properly cited. The copyright, license information and link to the original publication on (<http://www.ejomr.org>) must be included.